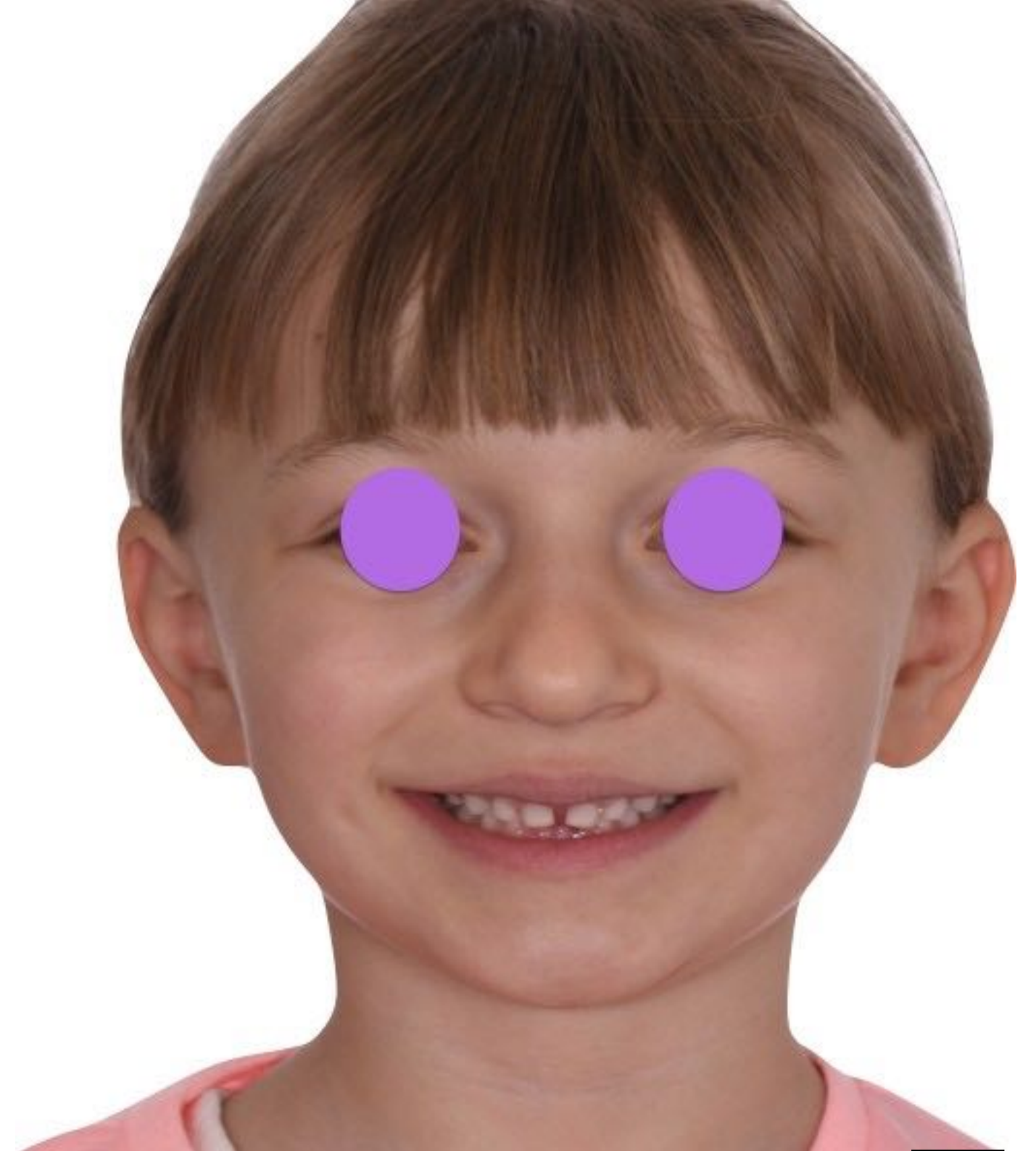

DDS Filippo Cardarelli

Dentist

Specialist in Orthodontics University of Milan



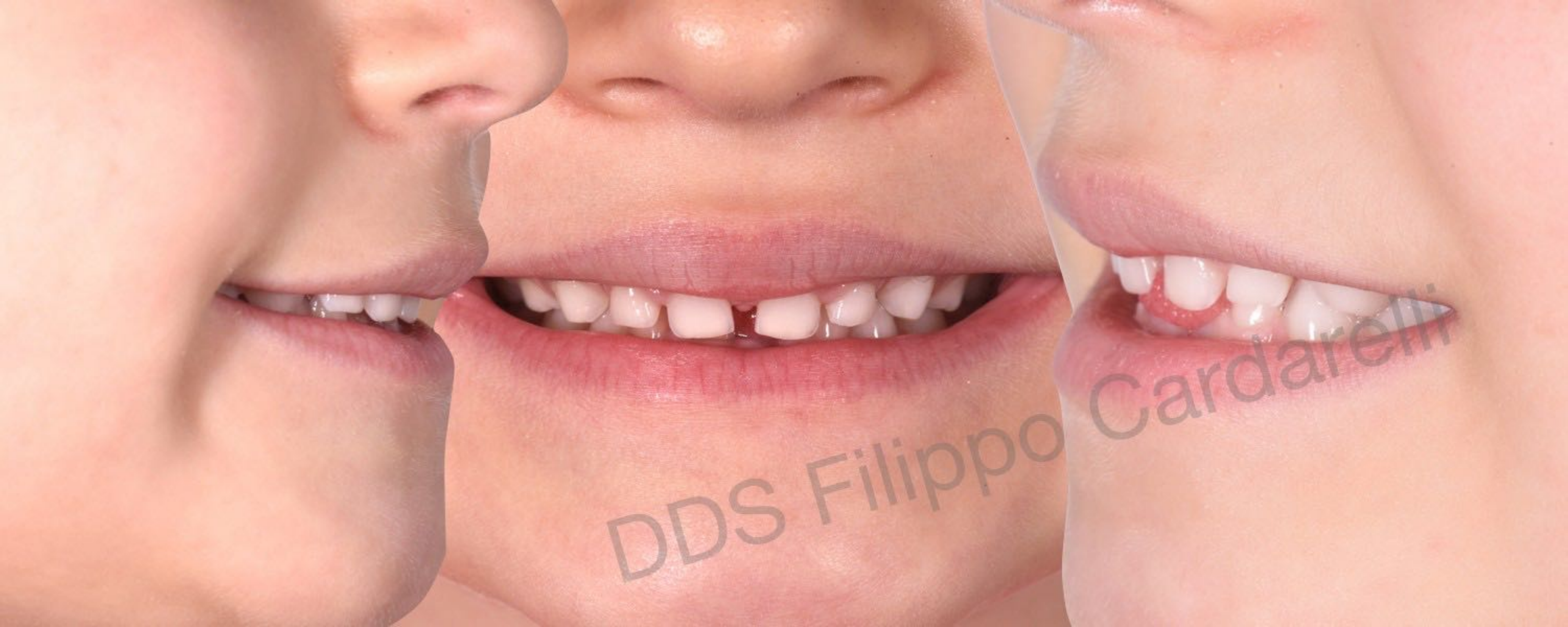IInd Classe Deep Bite

Patient 5 1/2 years old, Dental Class II, deep bite and normo skeletal, nocturnal grinding, postural alteration.

The therapeutic sequence involves the following steps:

- Motivation
- Speech therapy
- Elastodontic therapy , AMCOP Integral

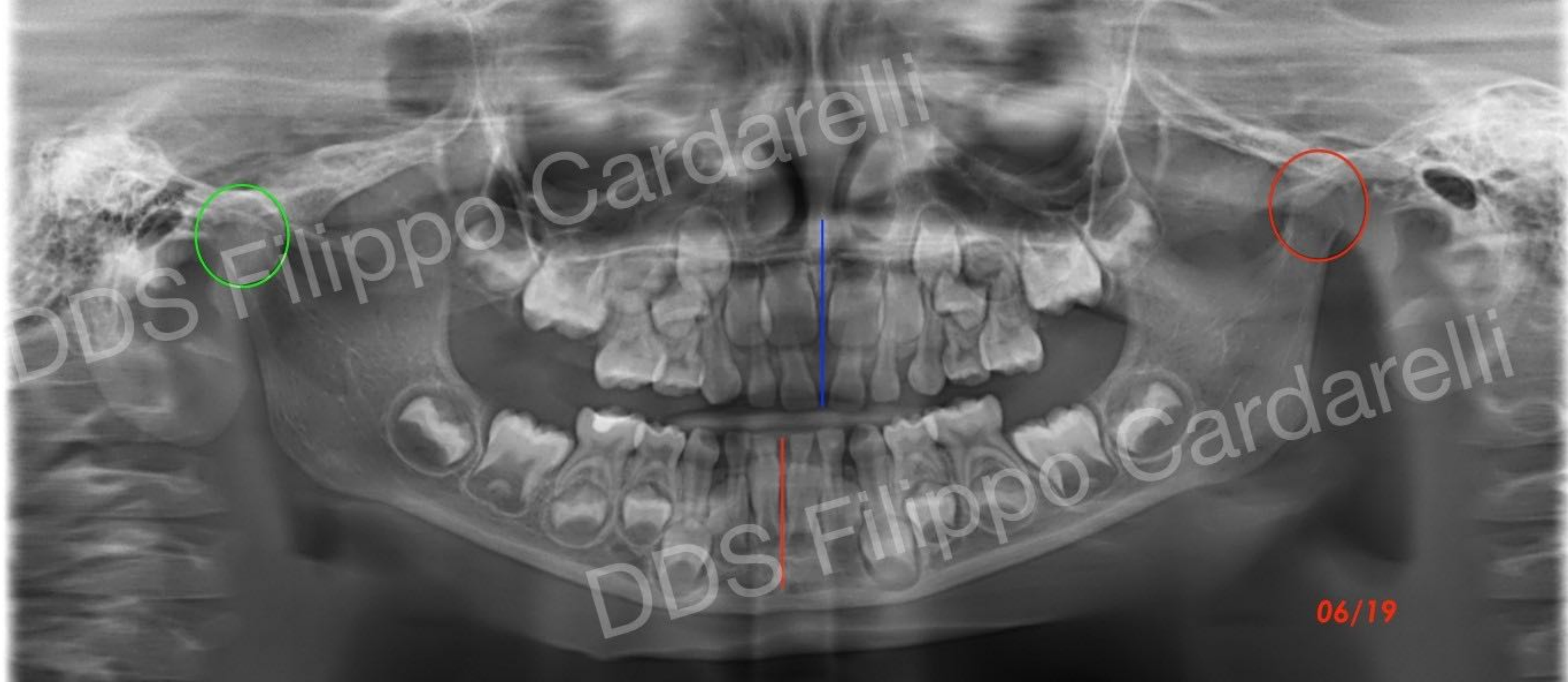
DDS Filippo
Cardarelli



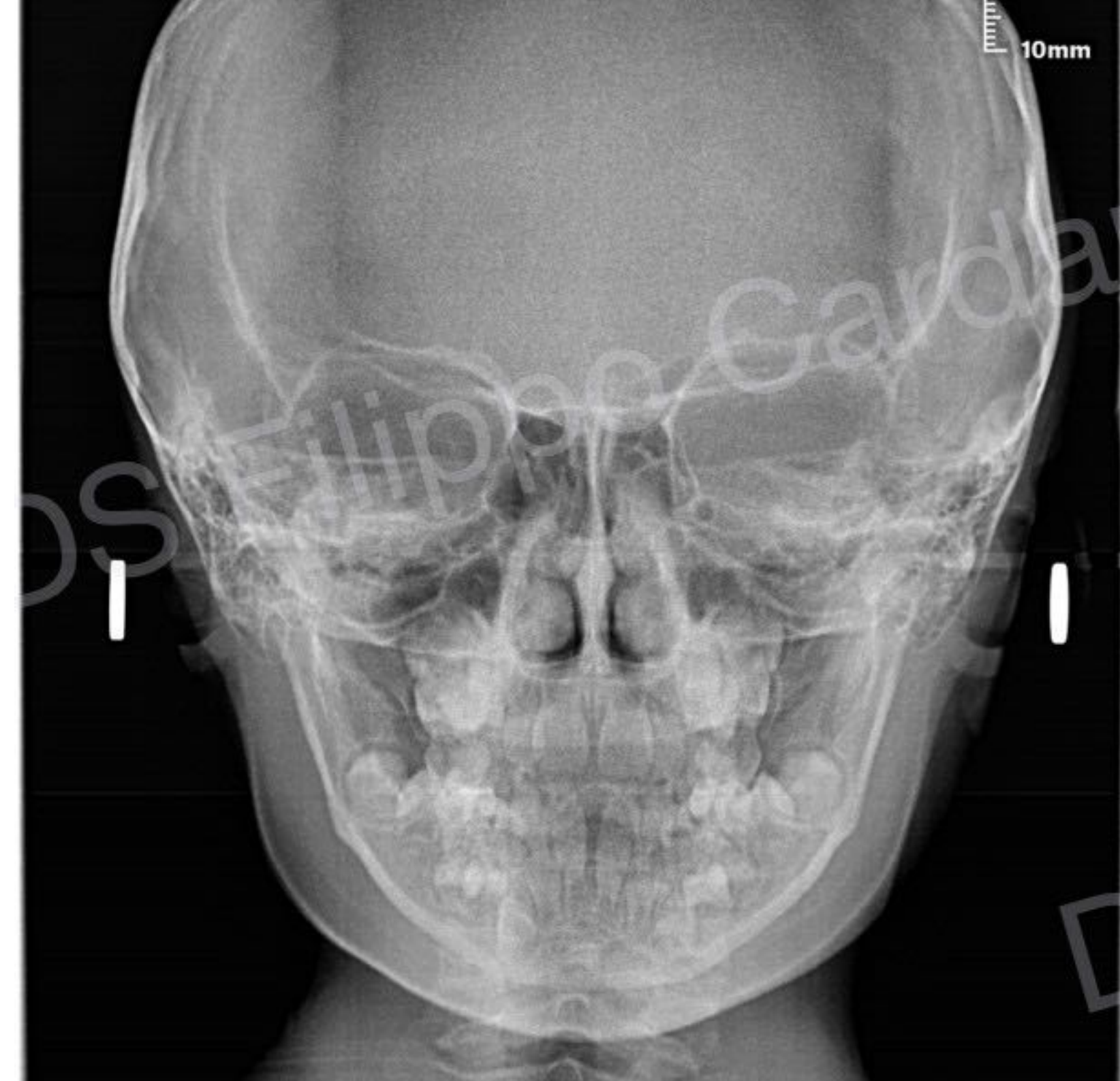DDS Filippo

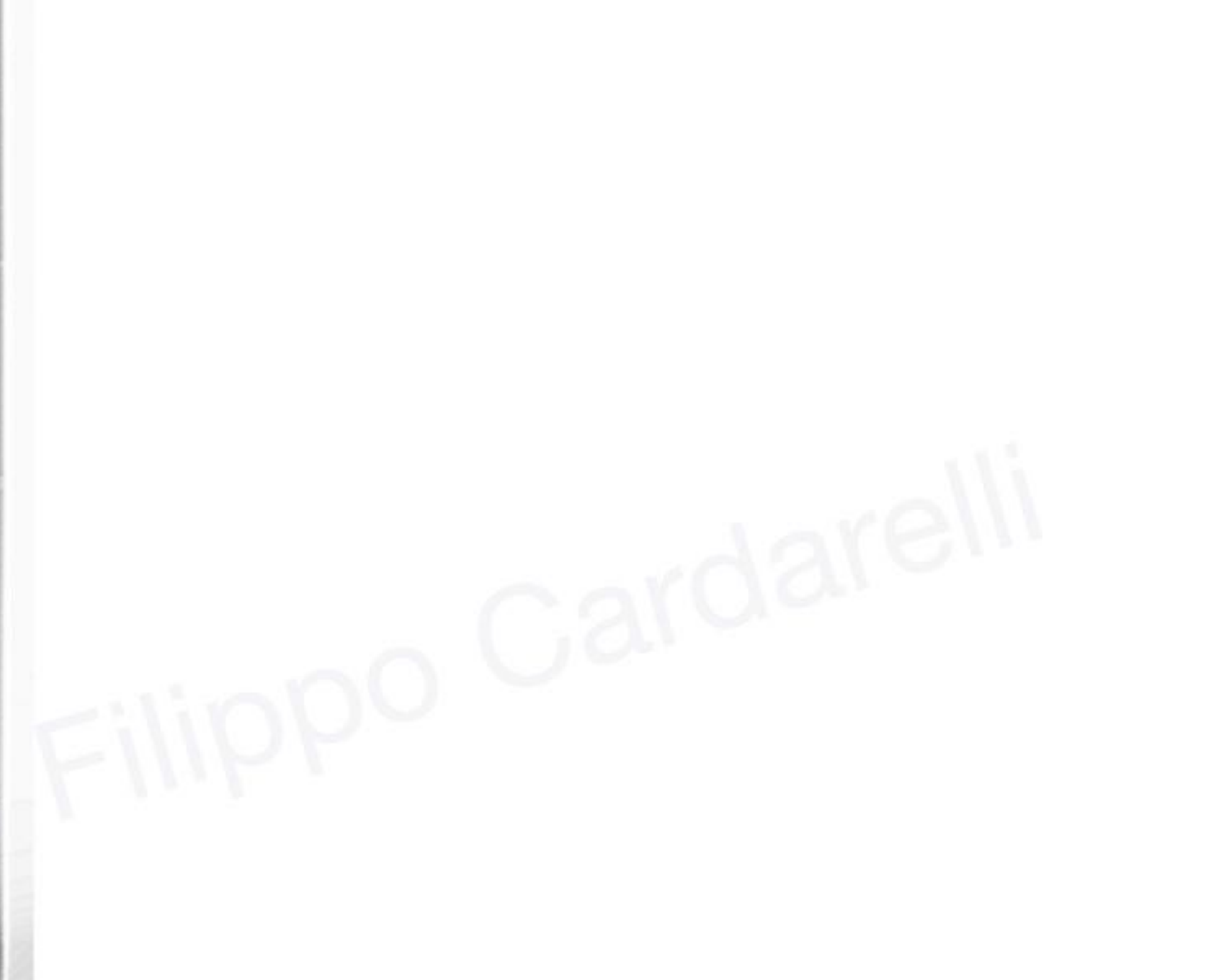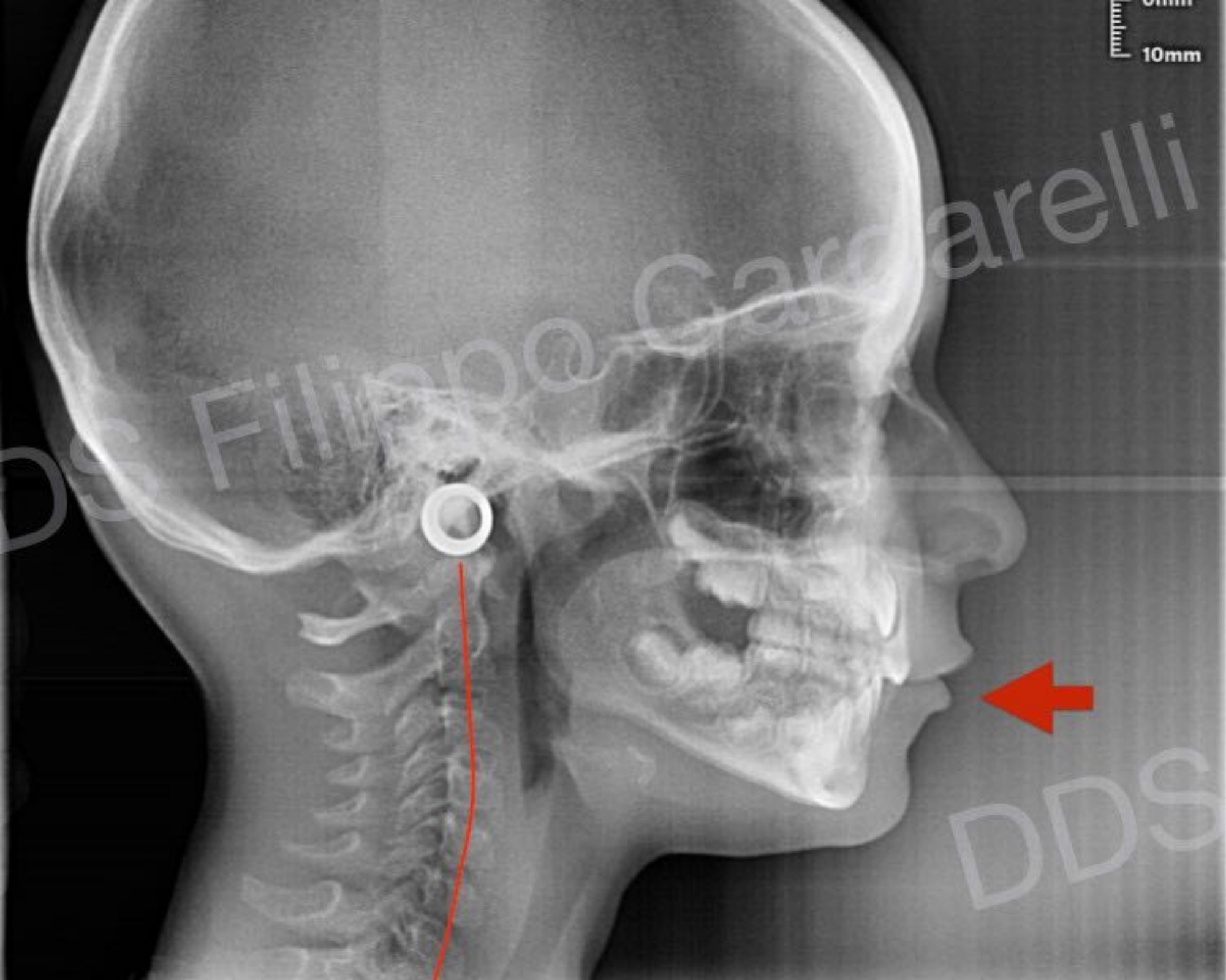
Cardarelli



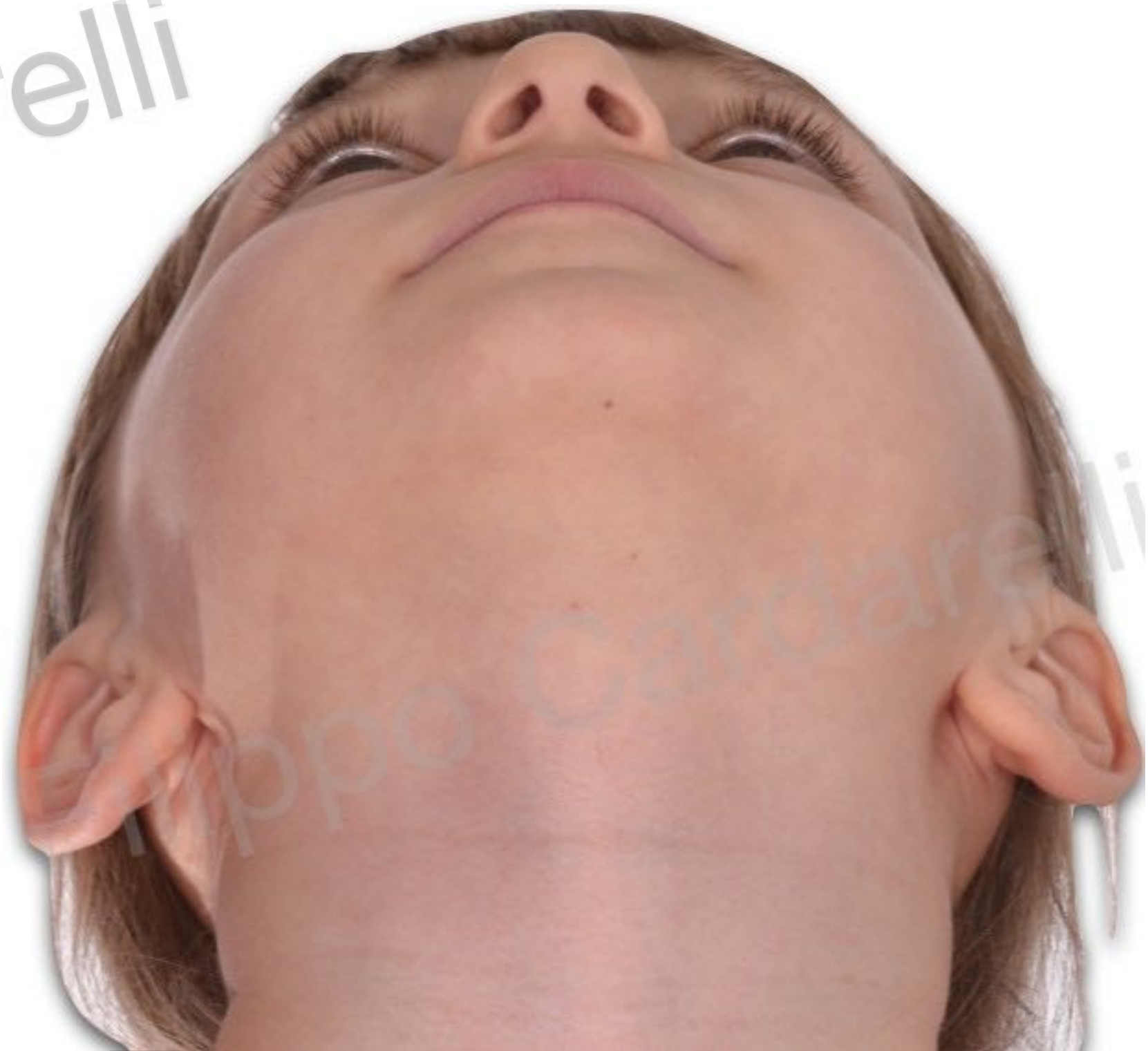

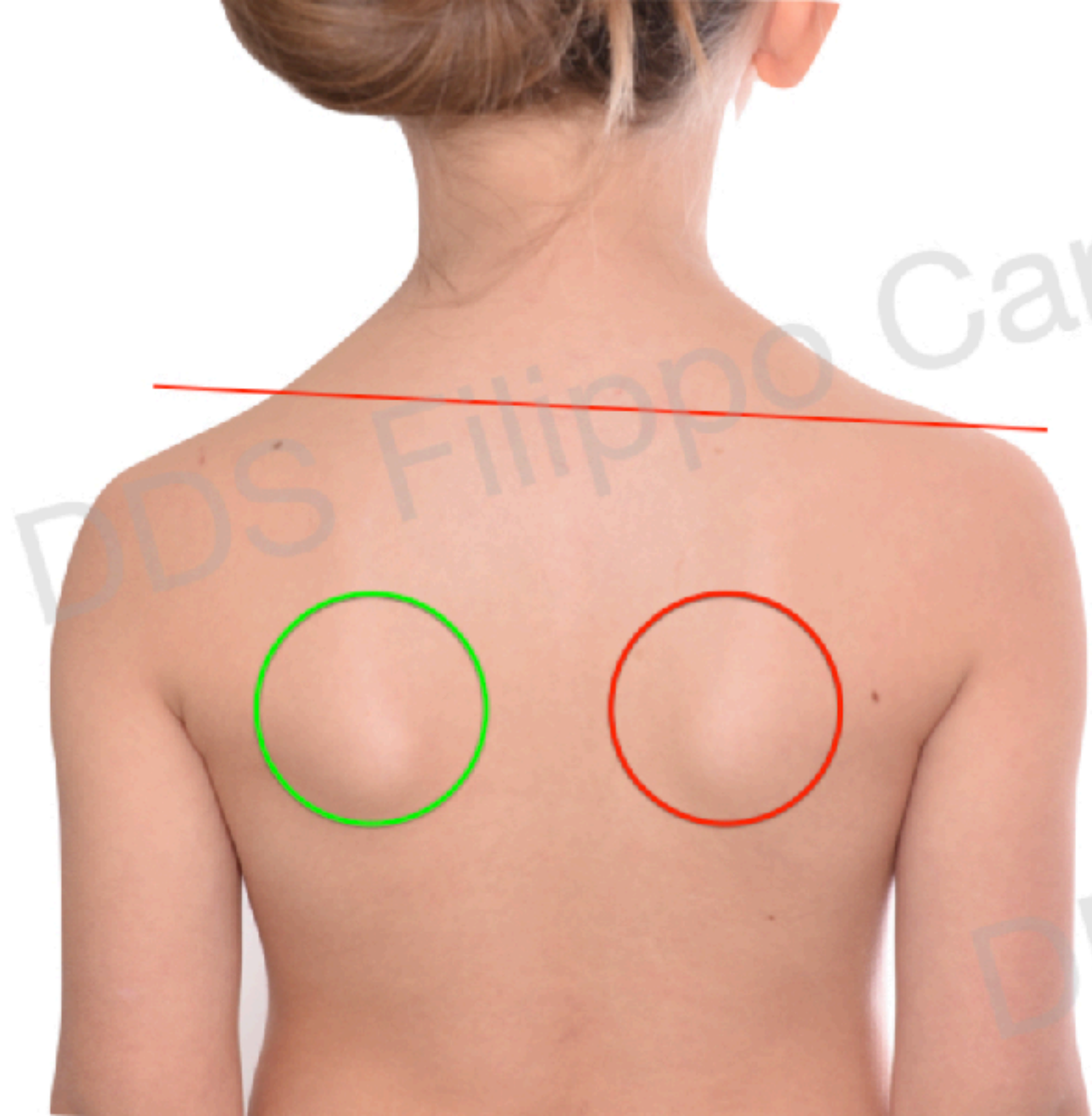
06/19

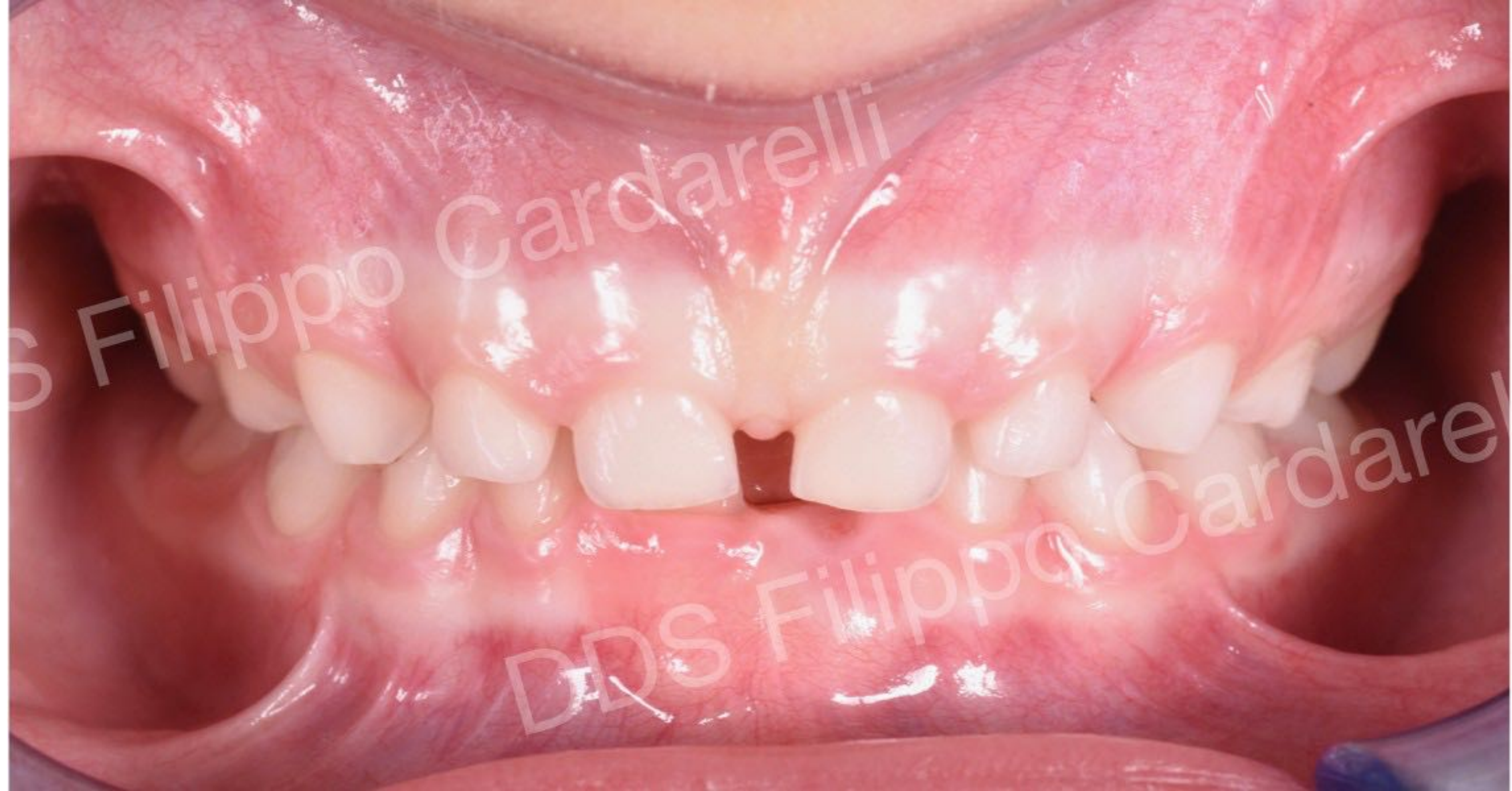


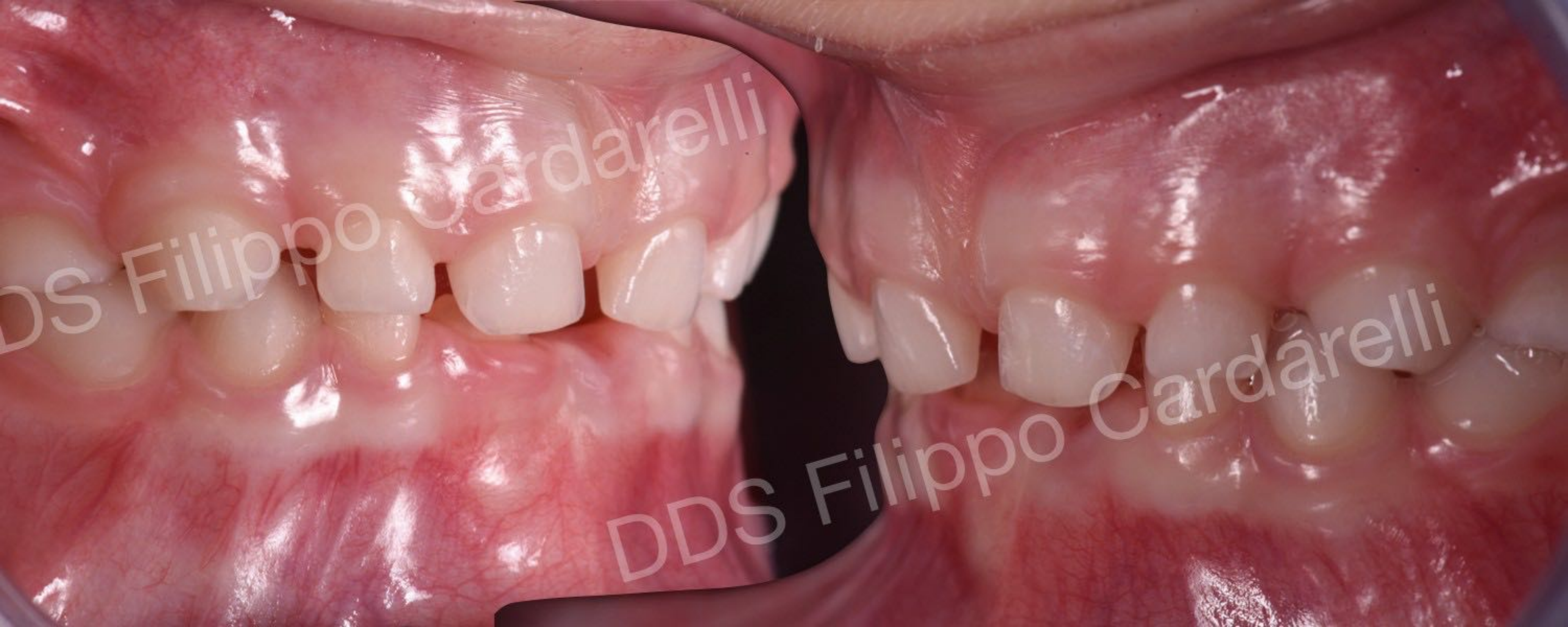
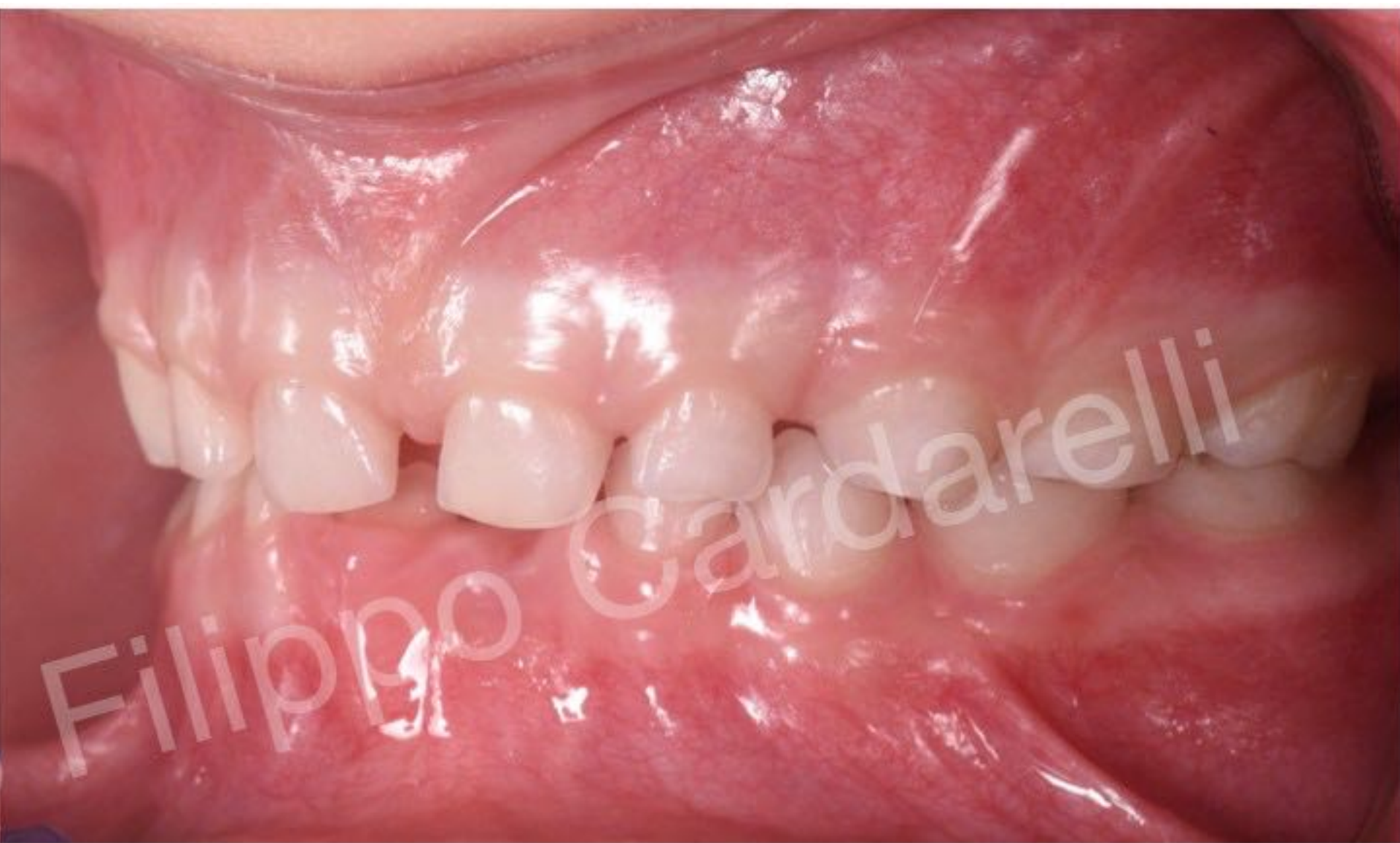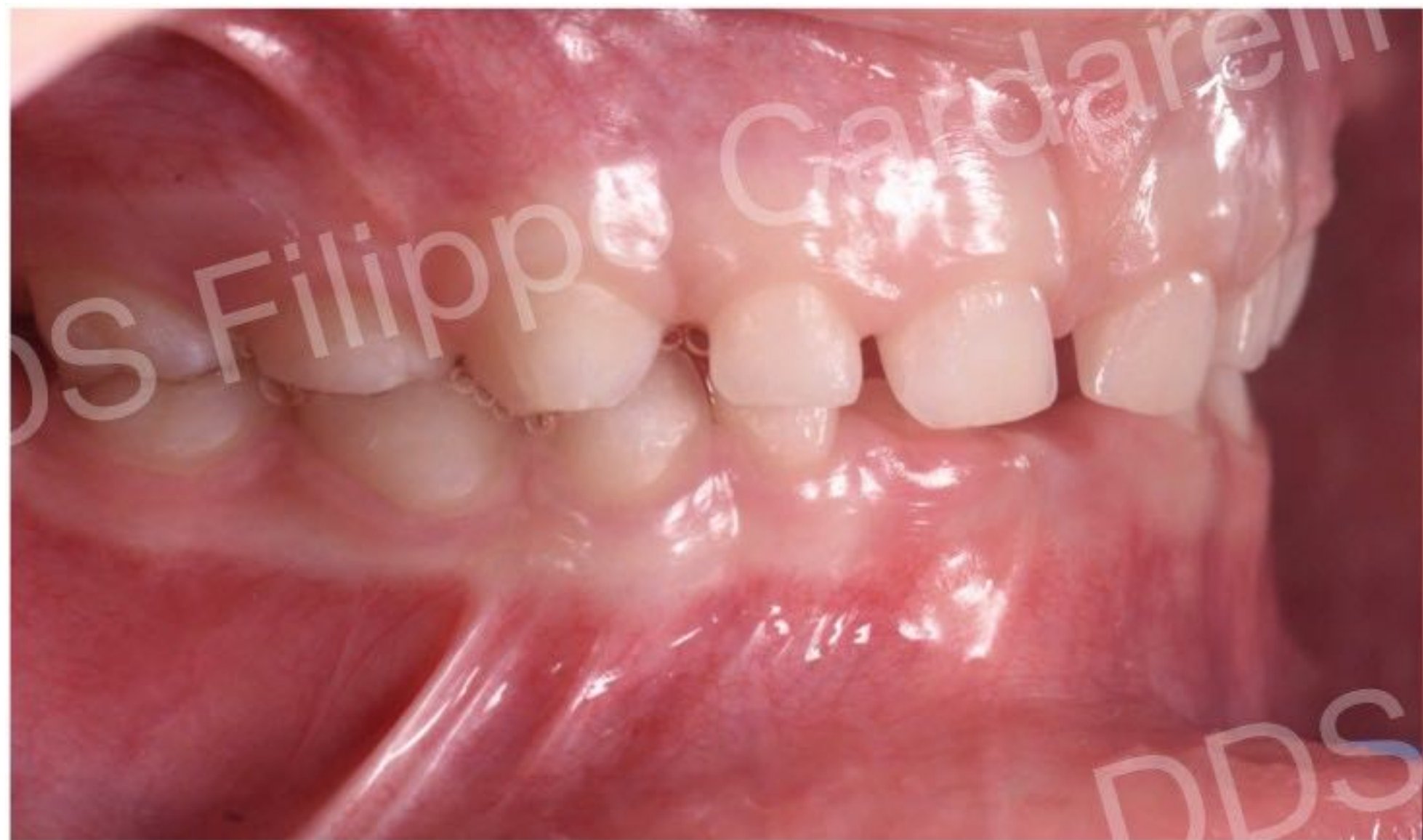DDS
Cardarelli

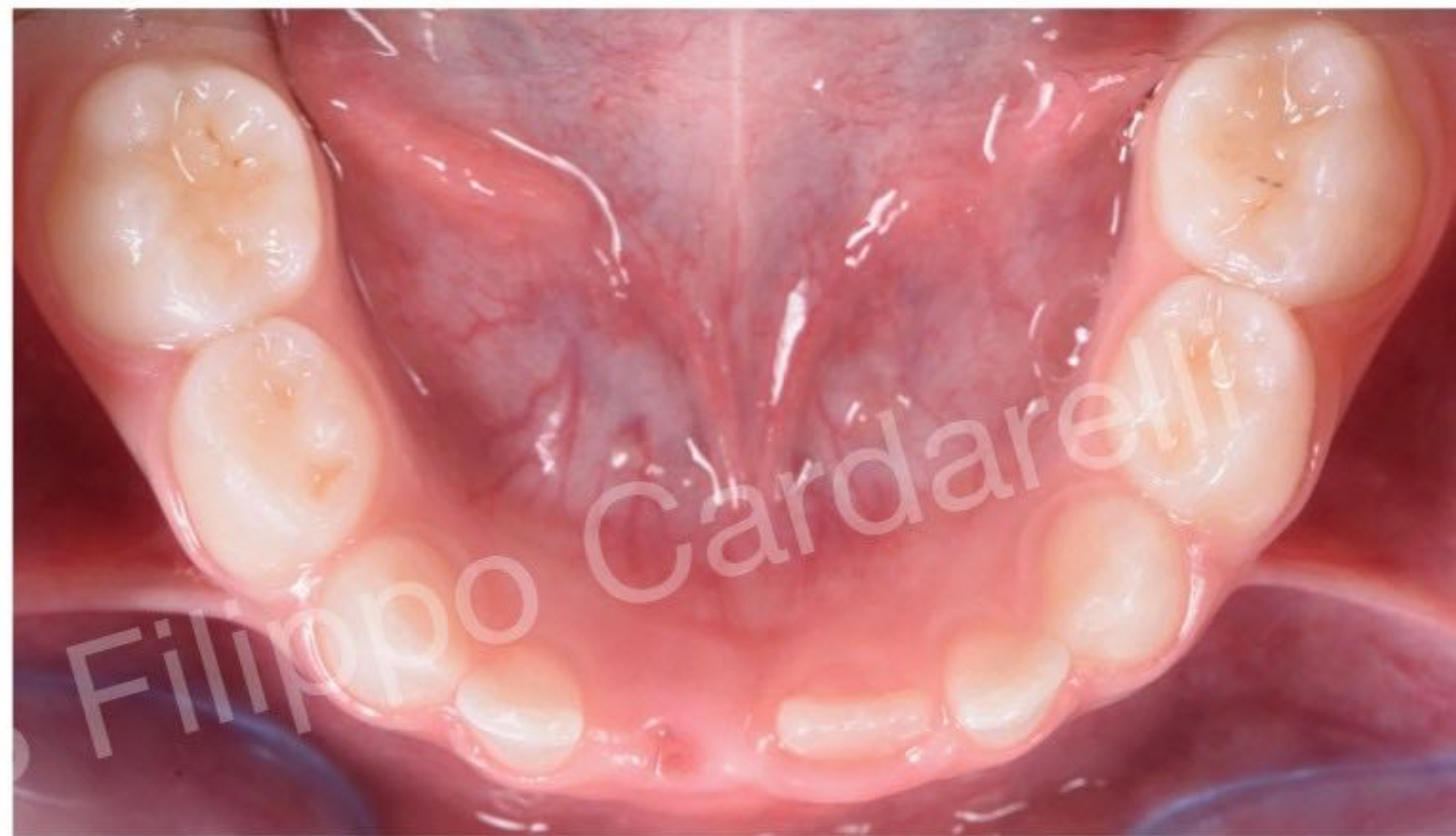
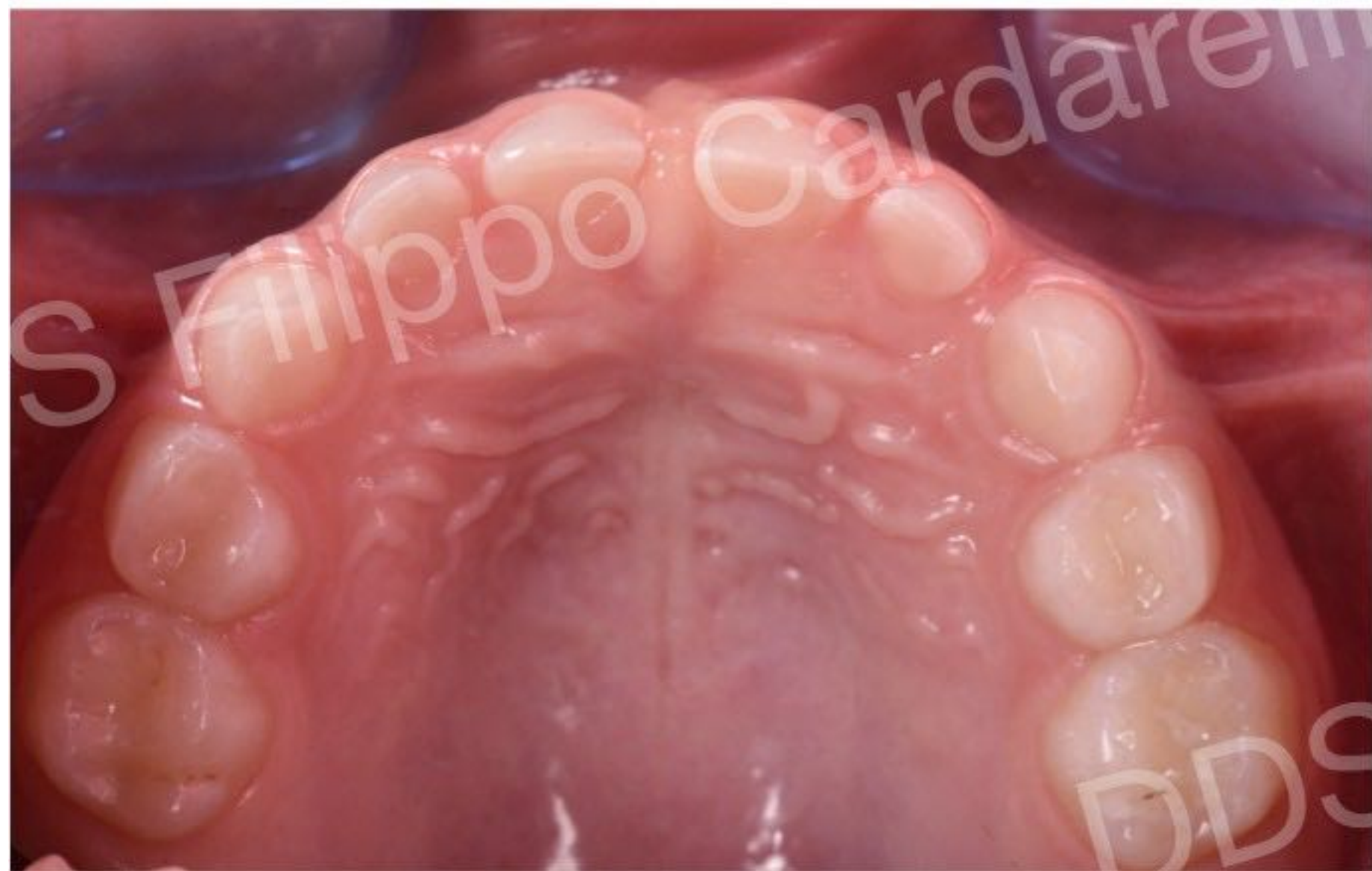


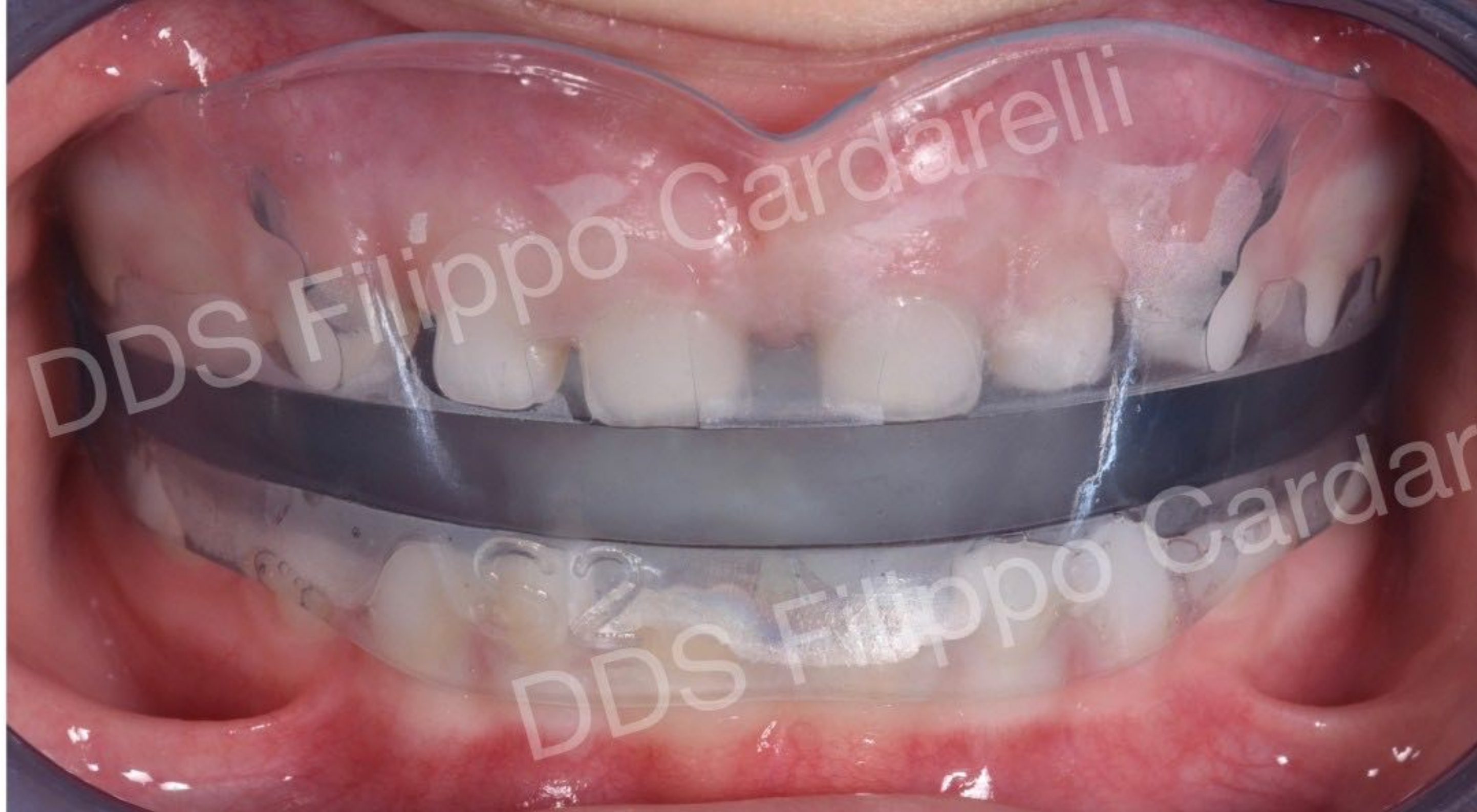


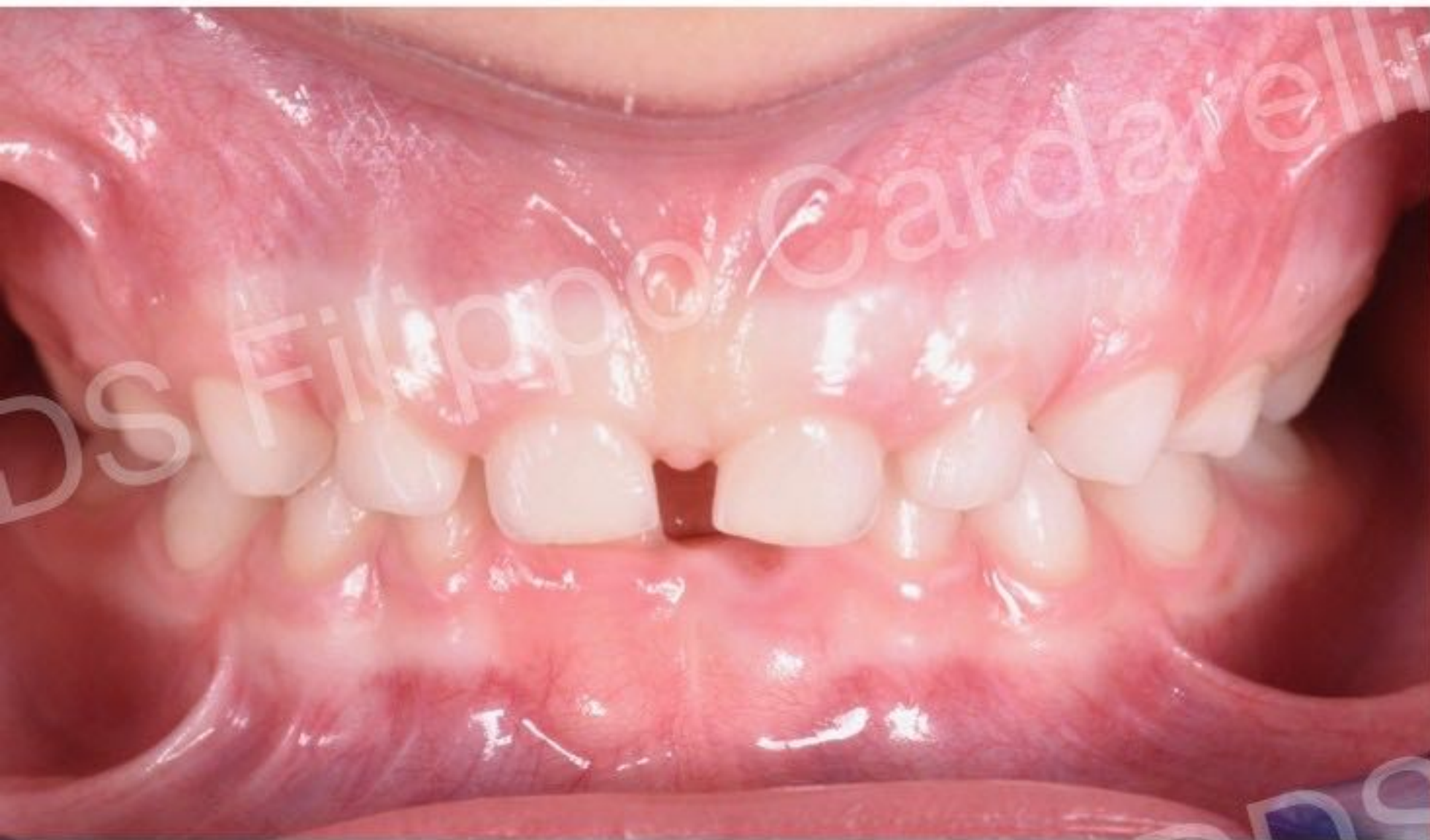




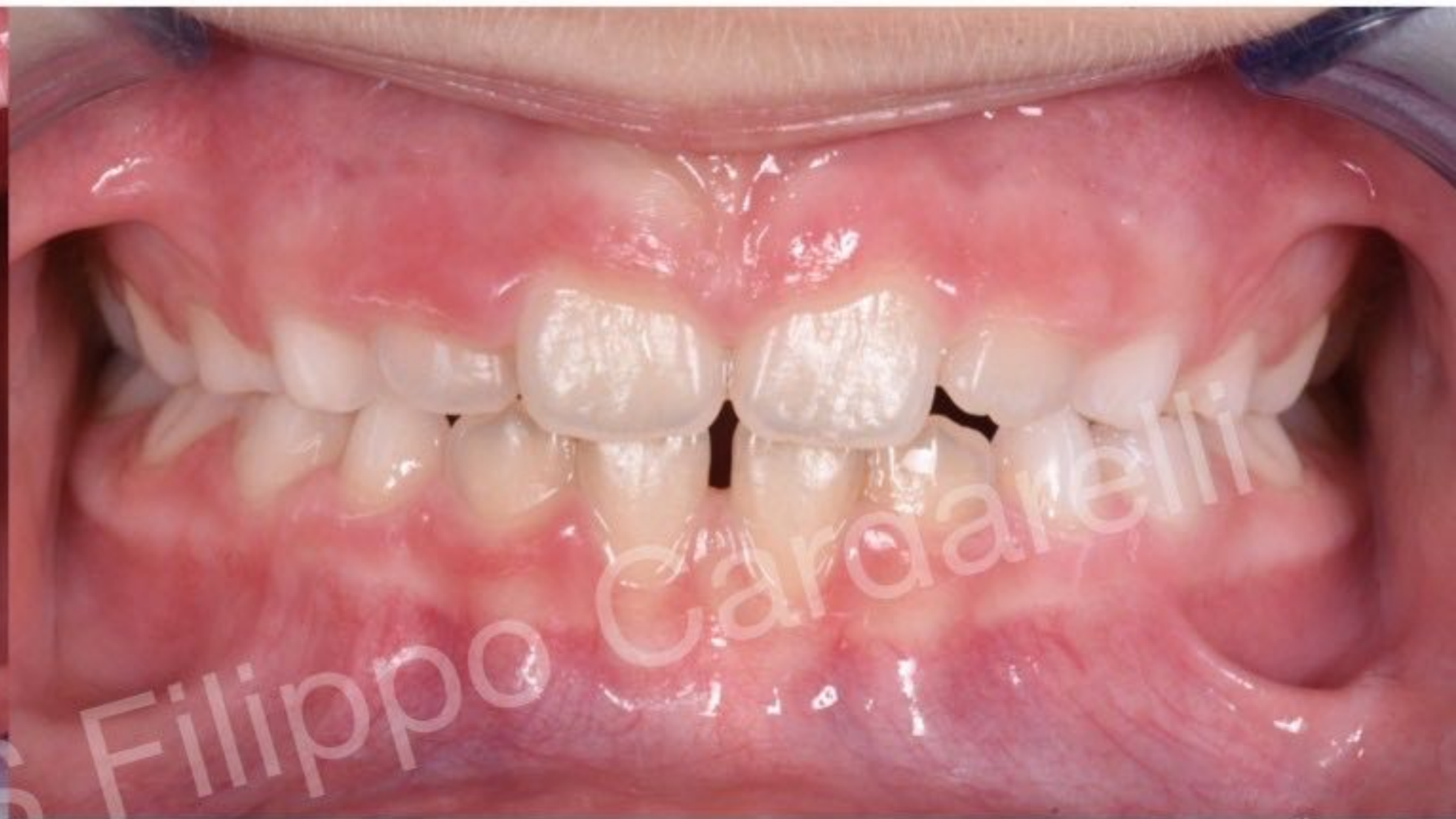



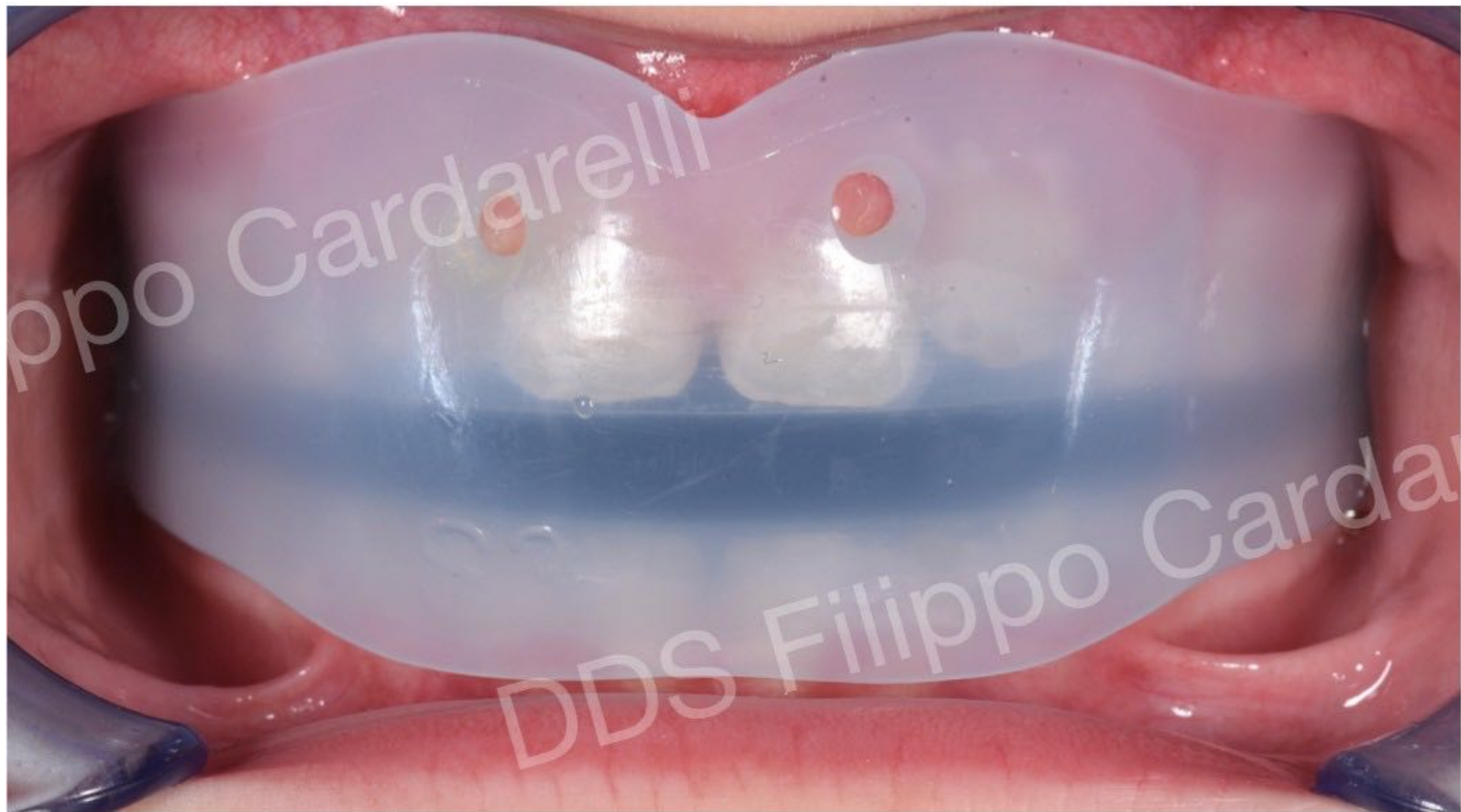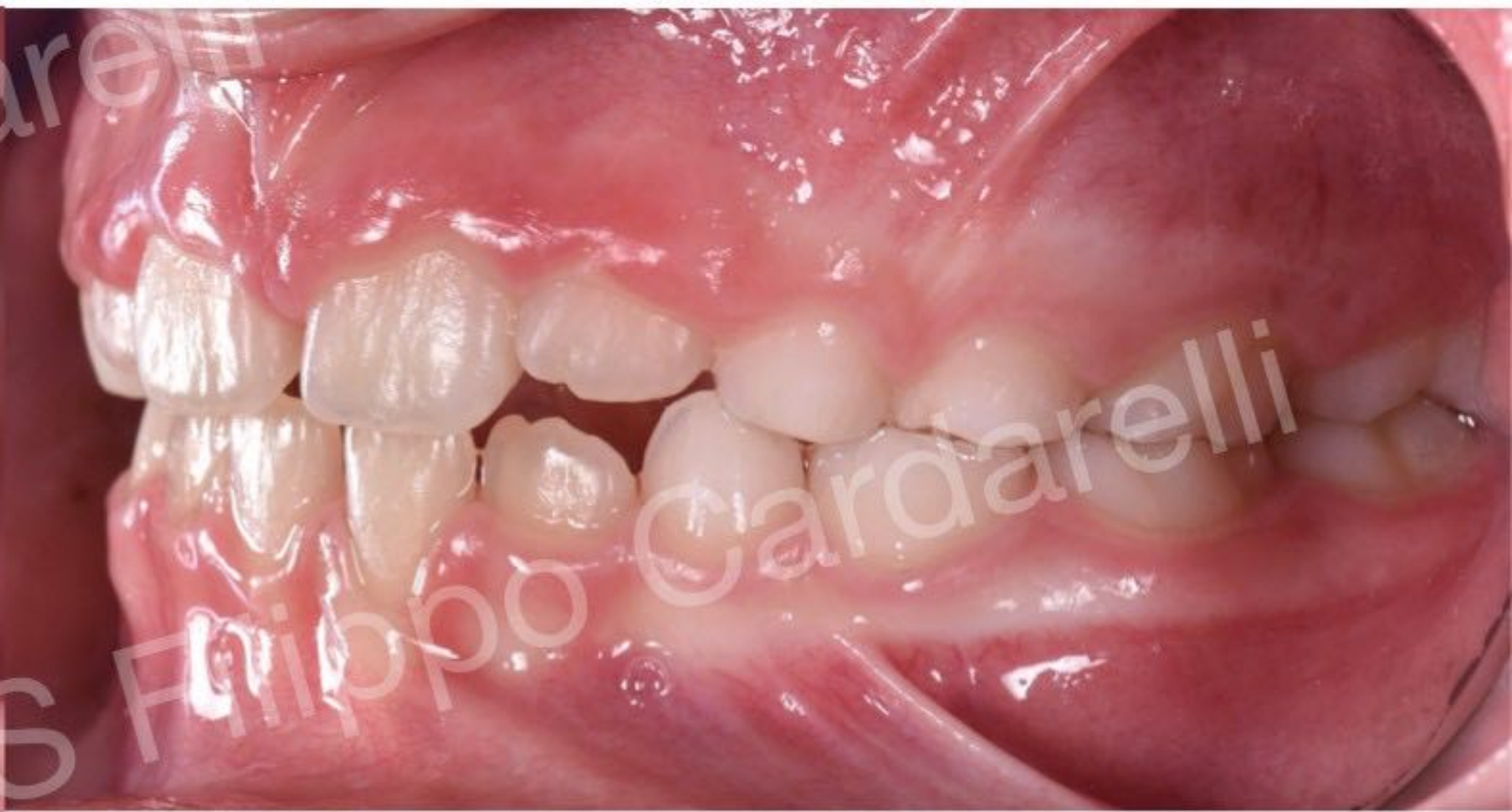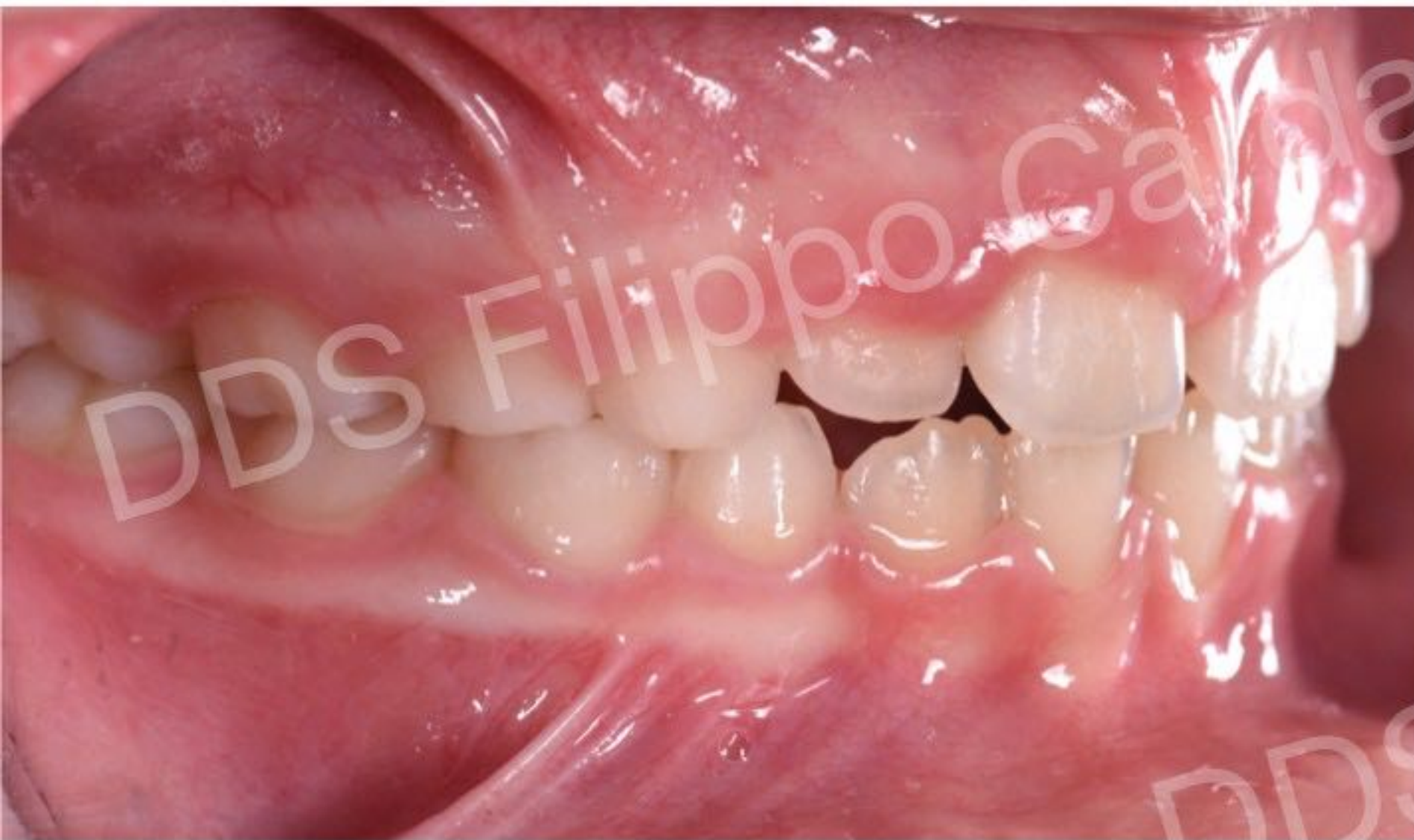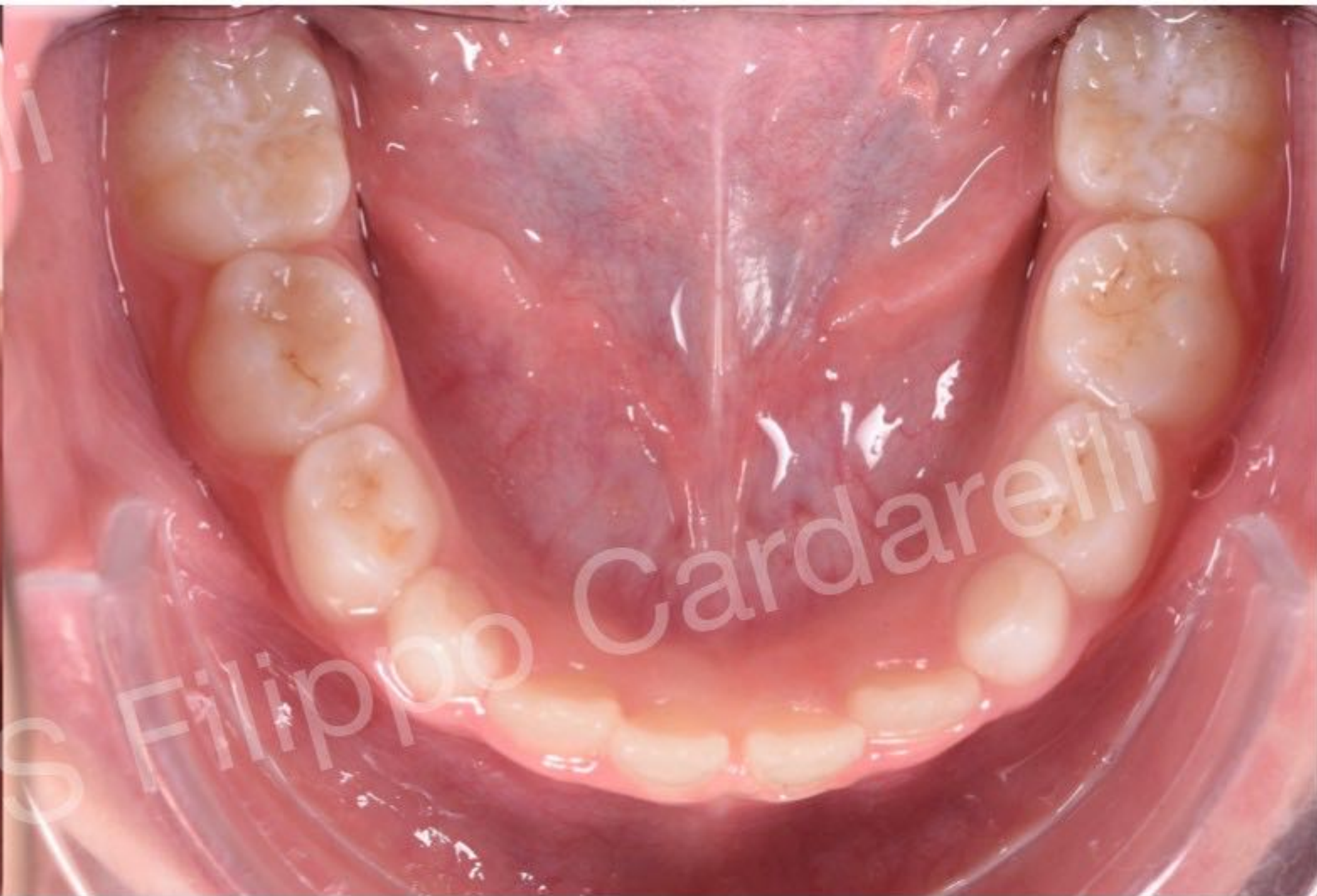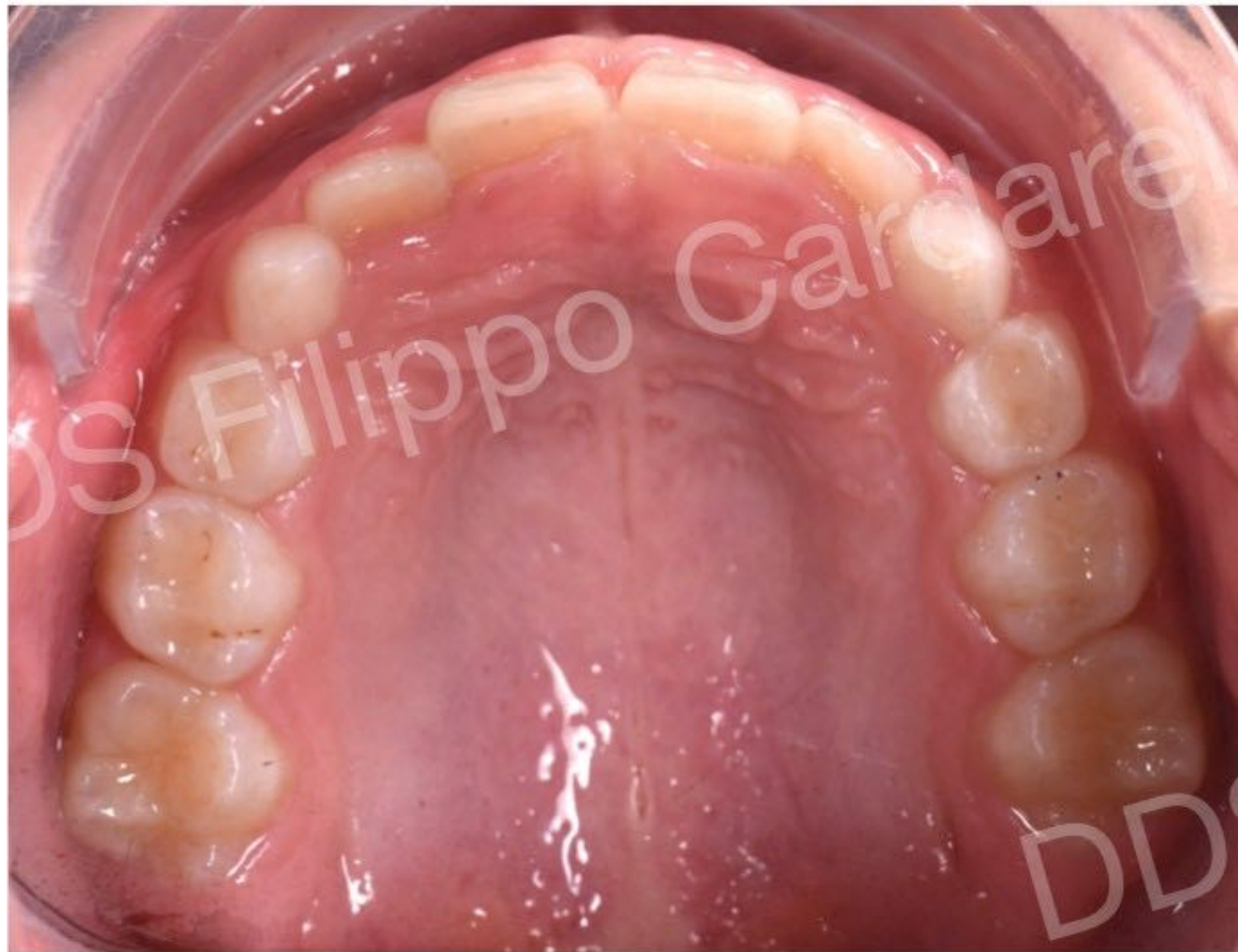06/19



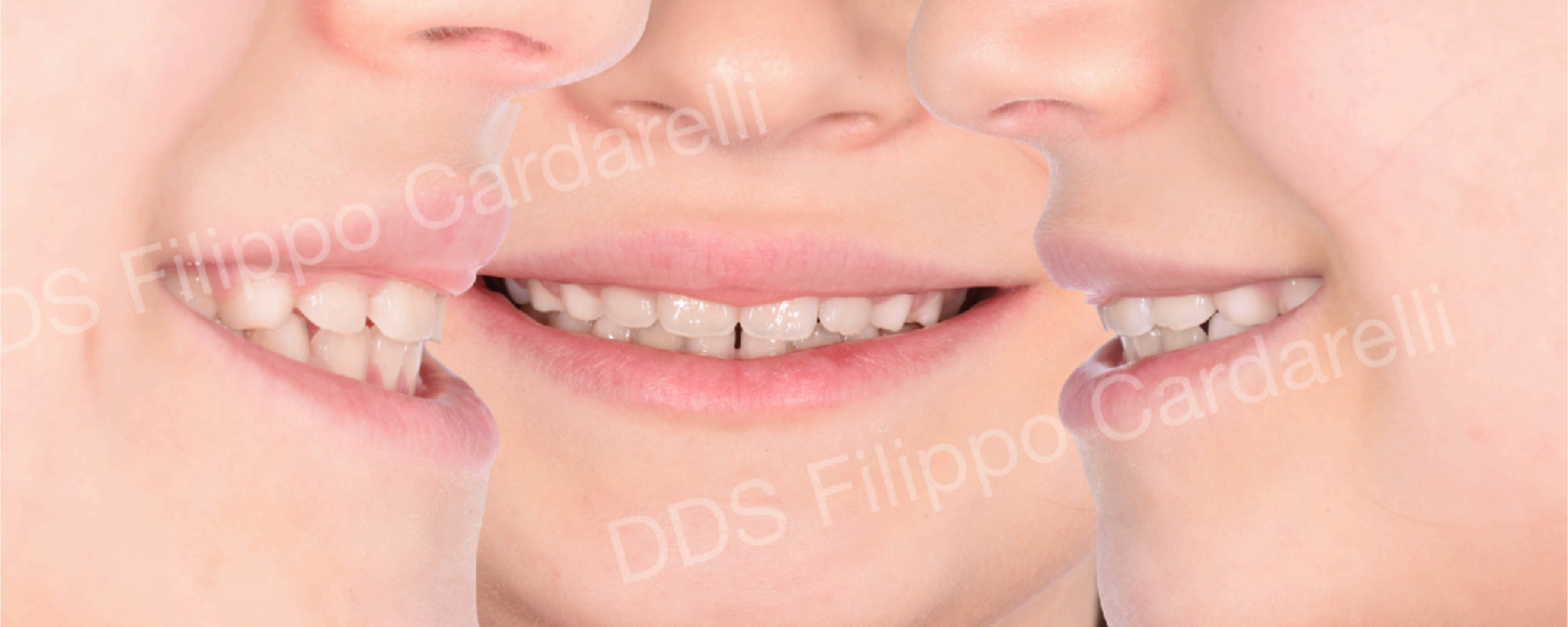10/20

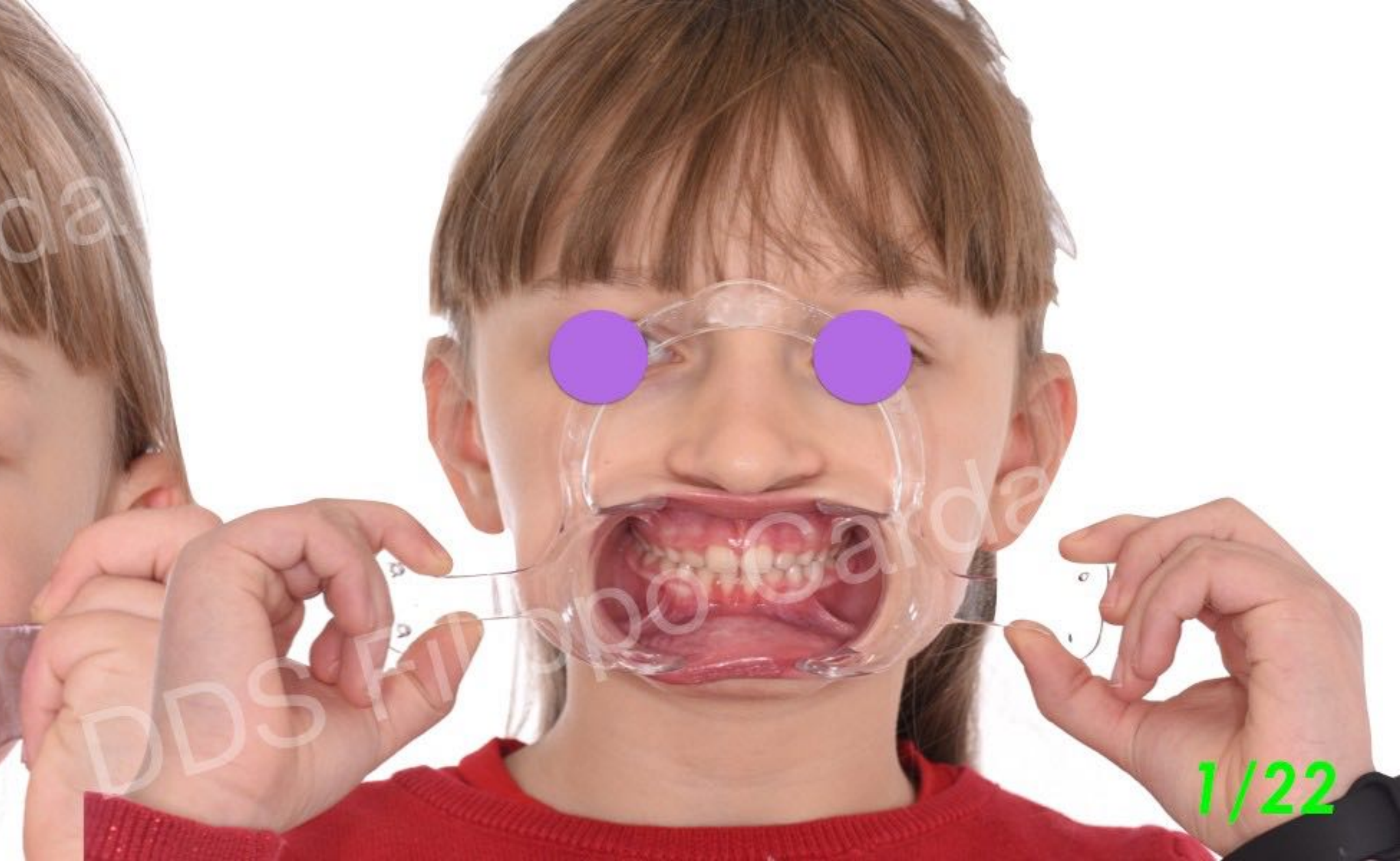
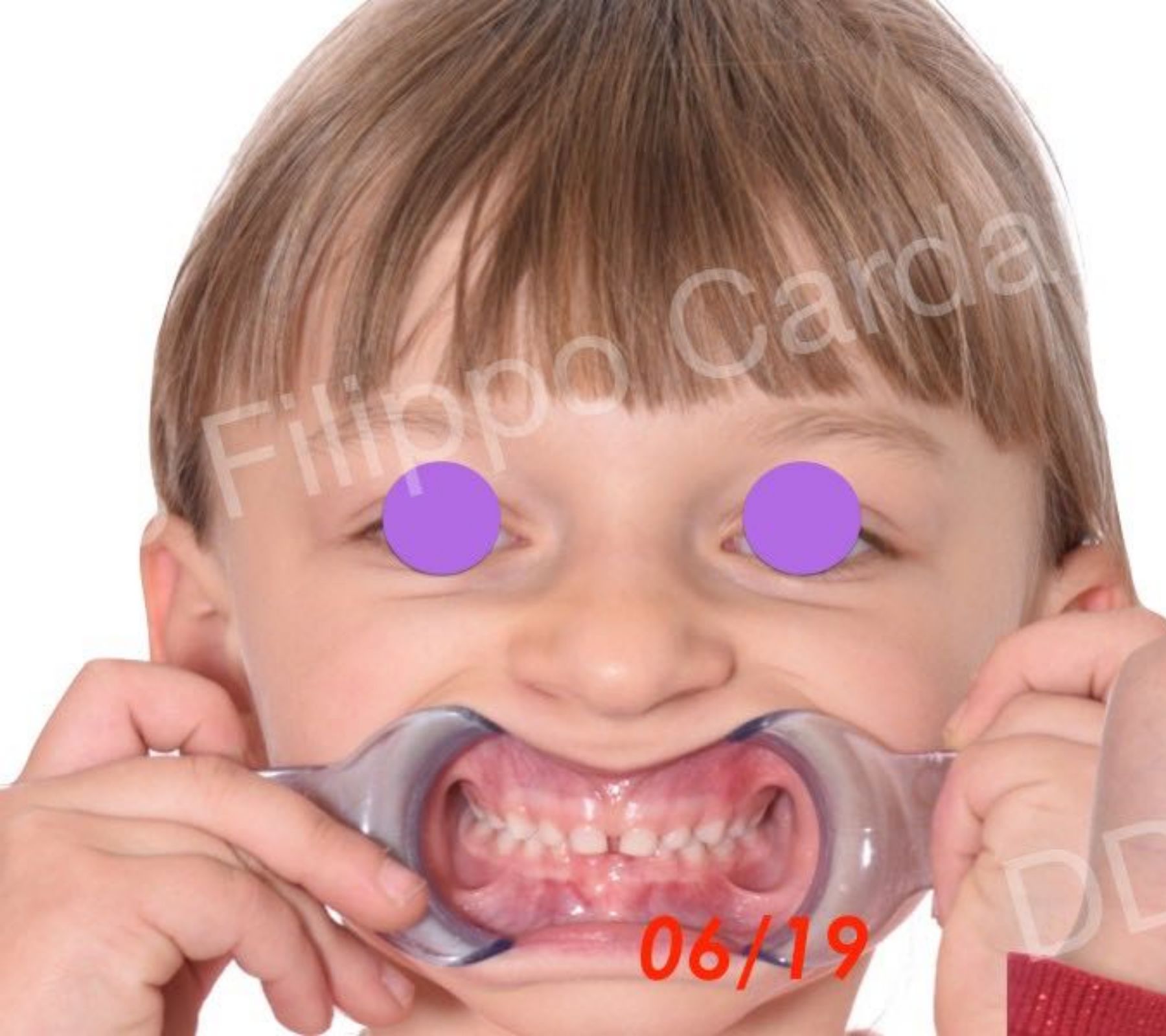


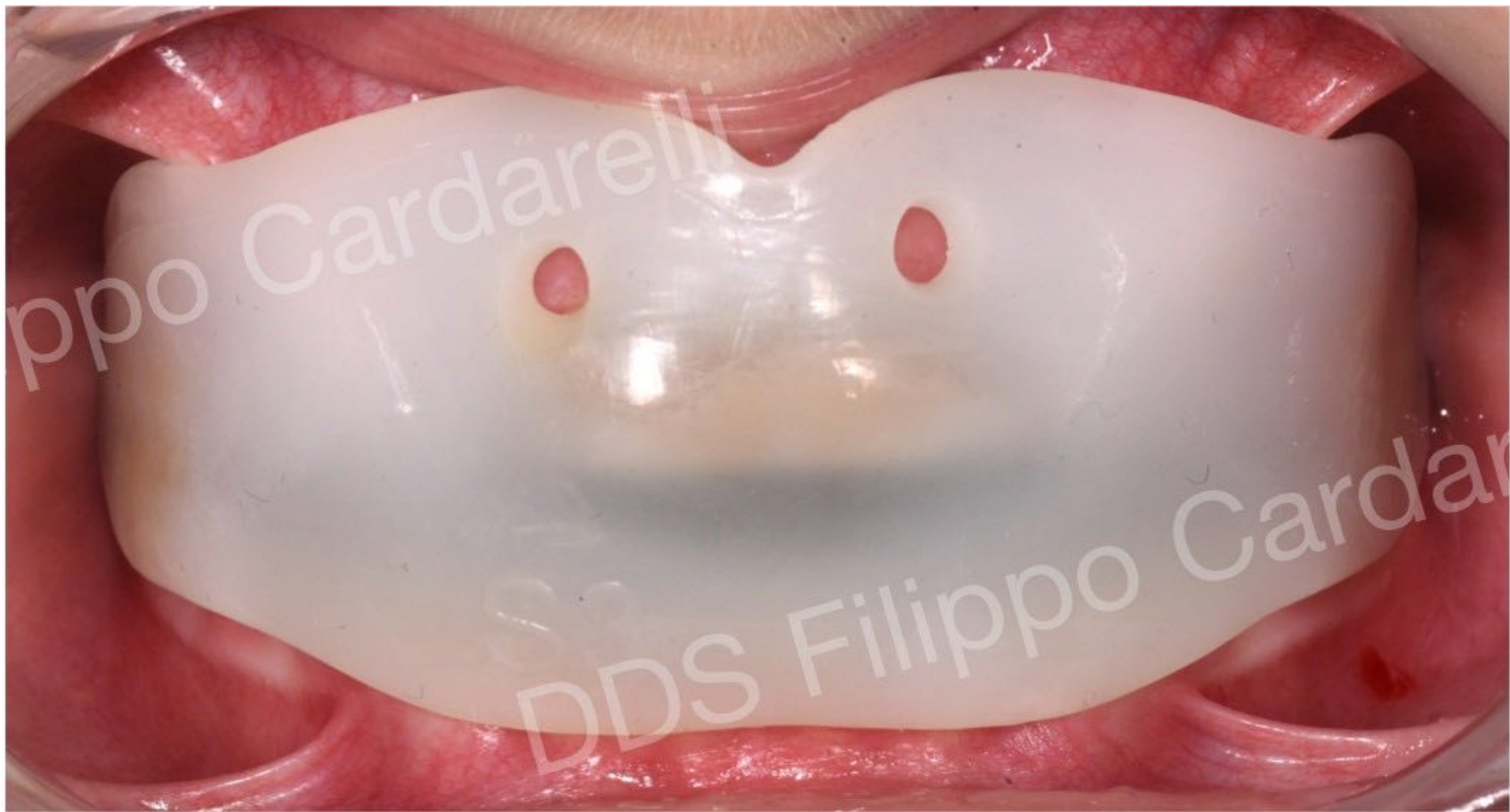

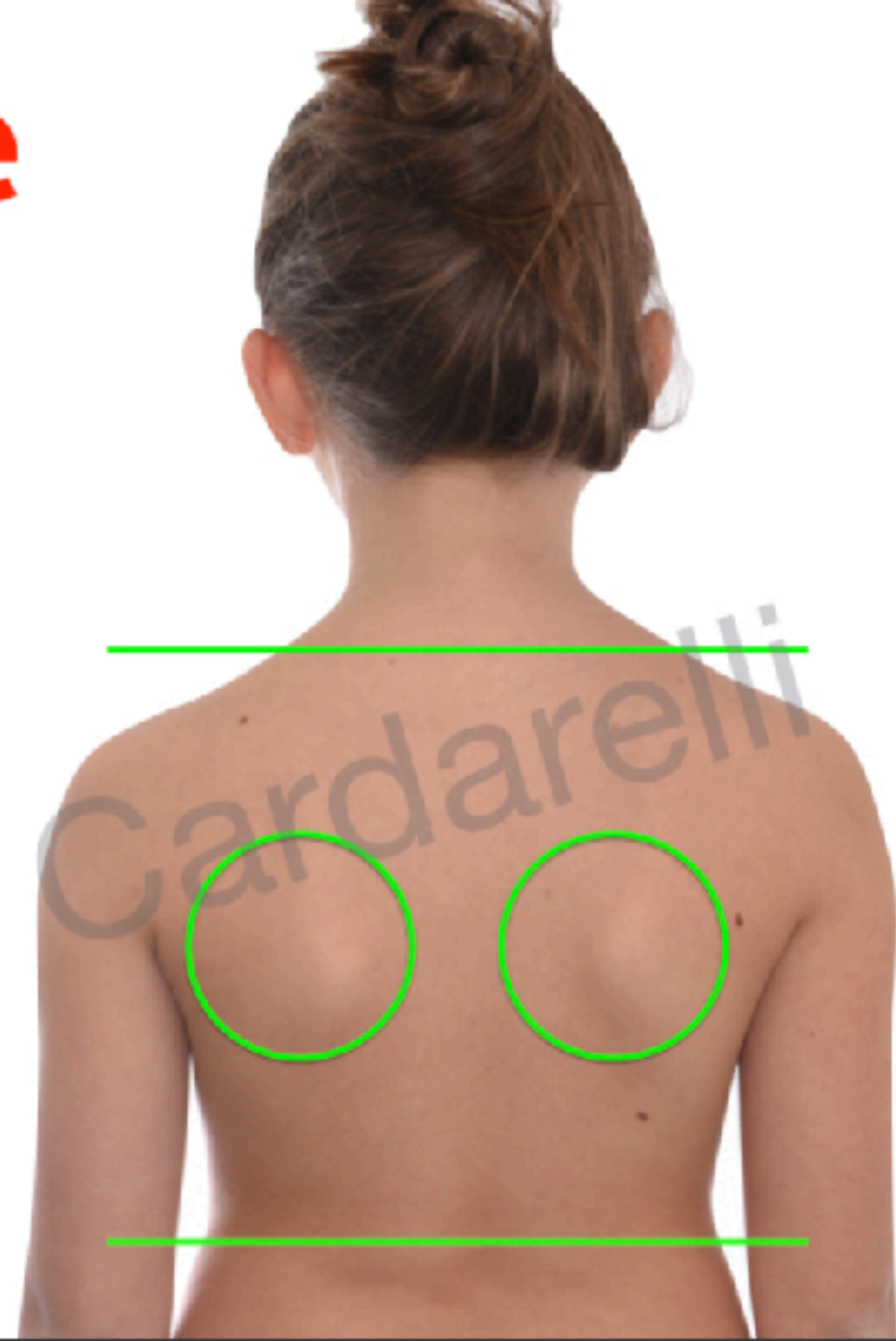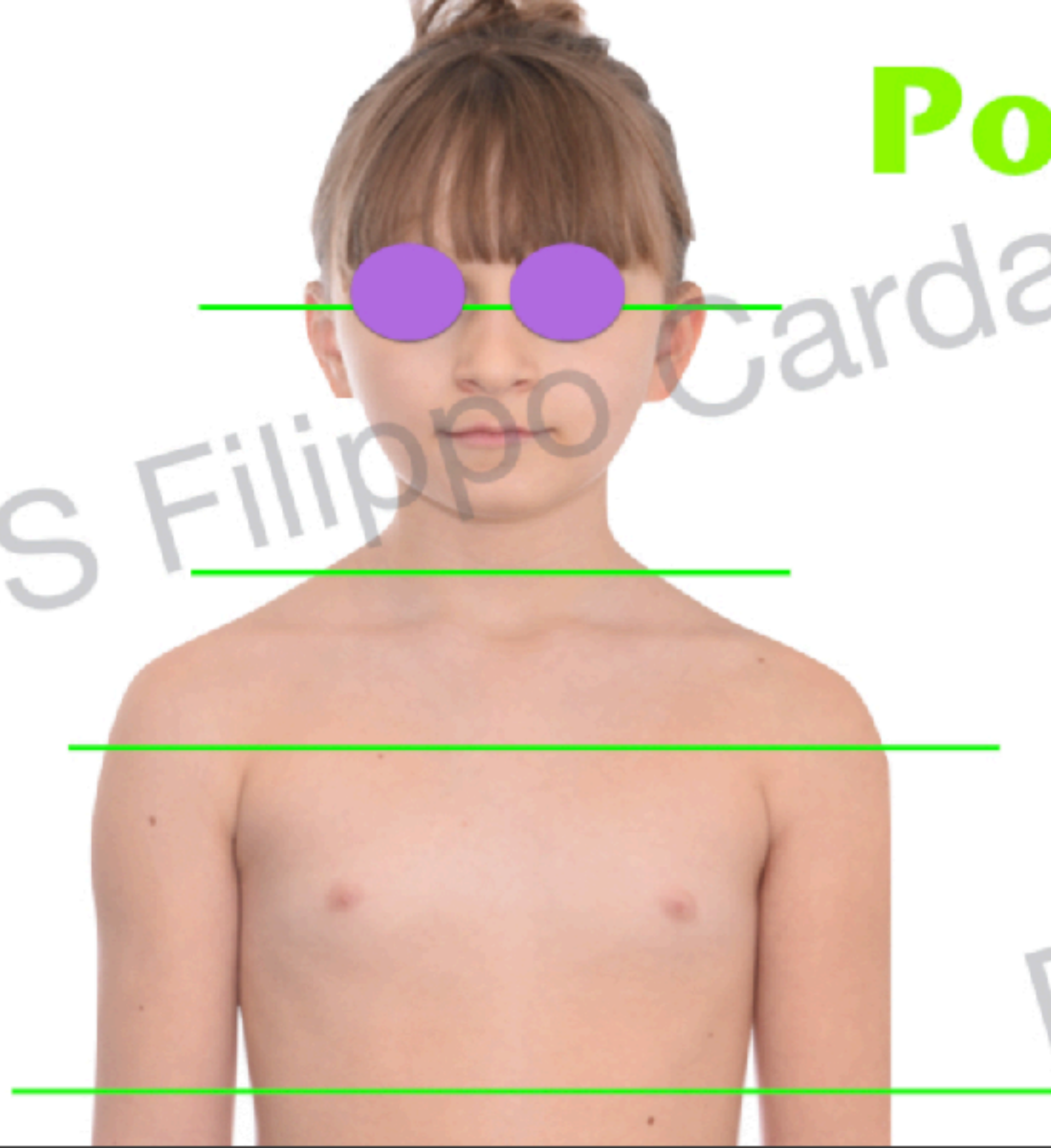








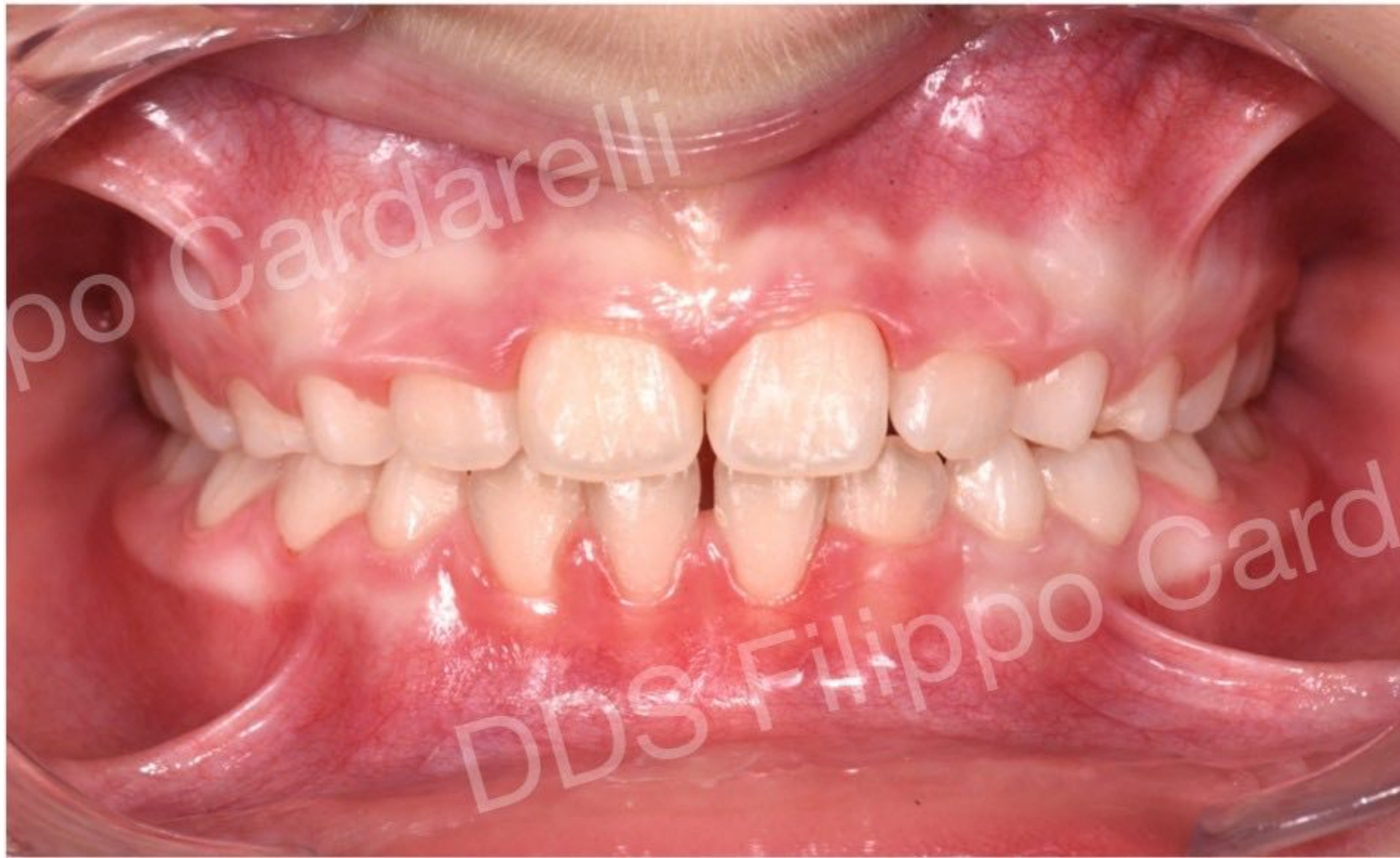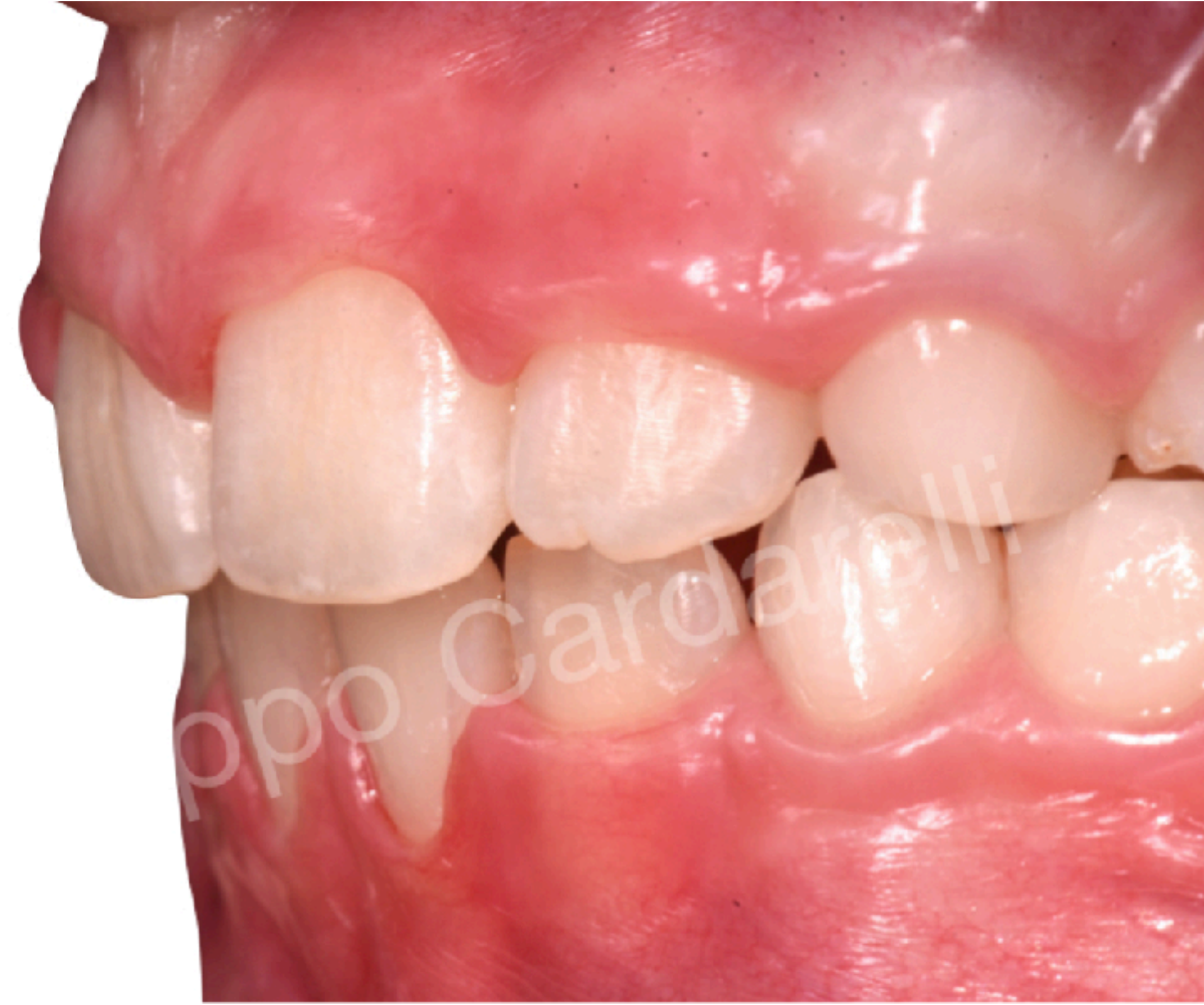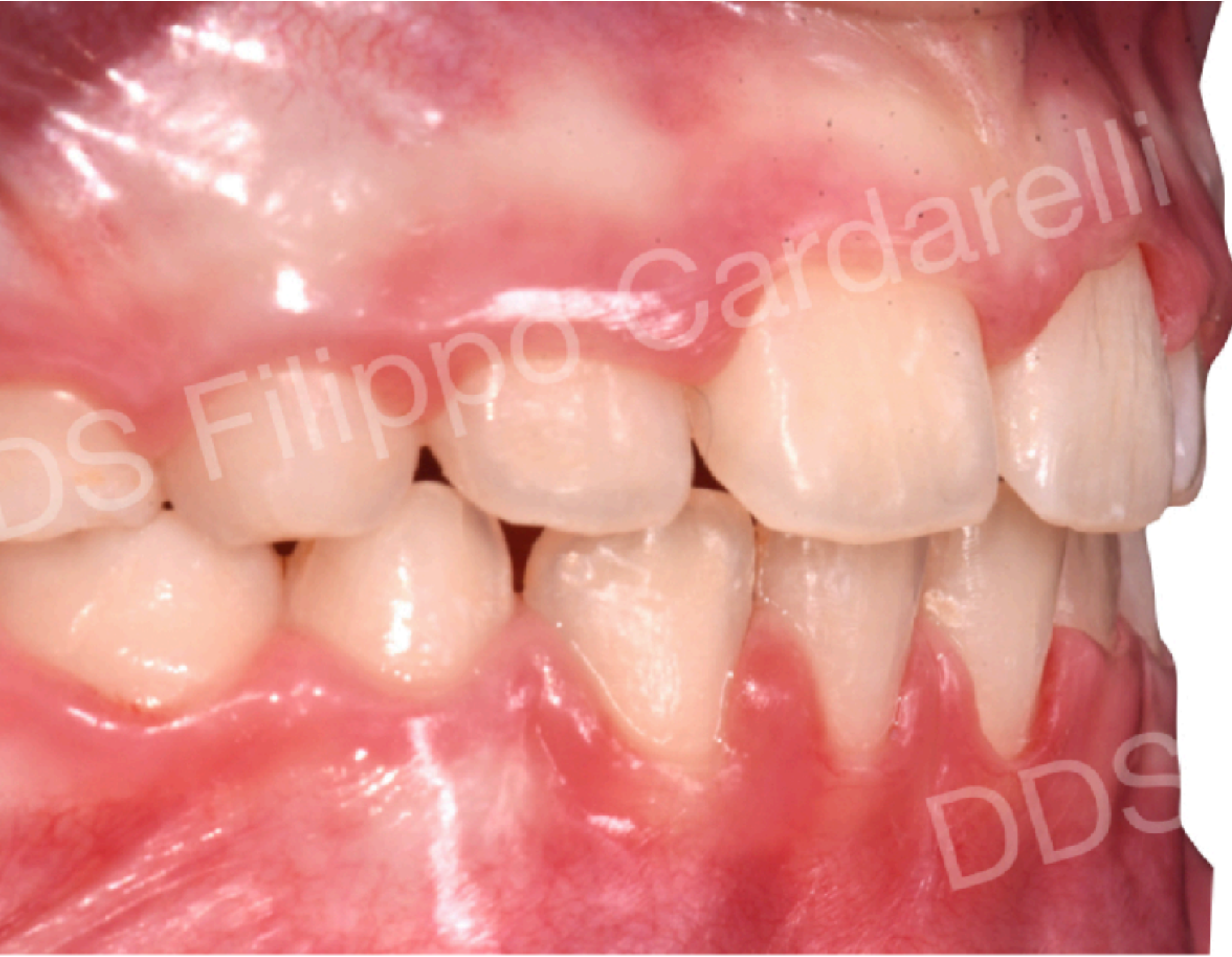Postural Line

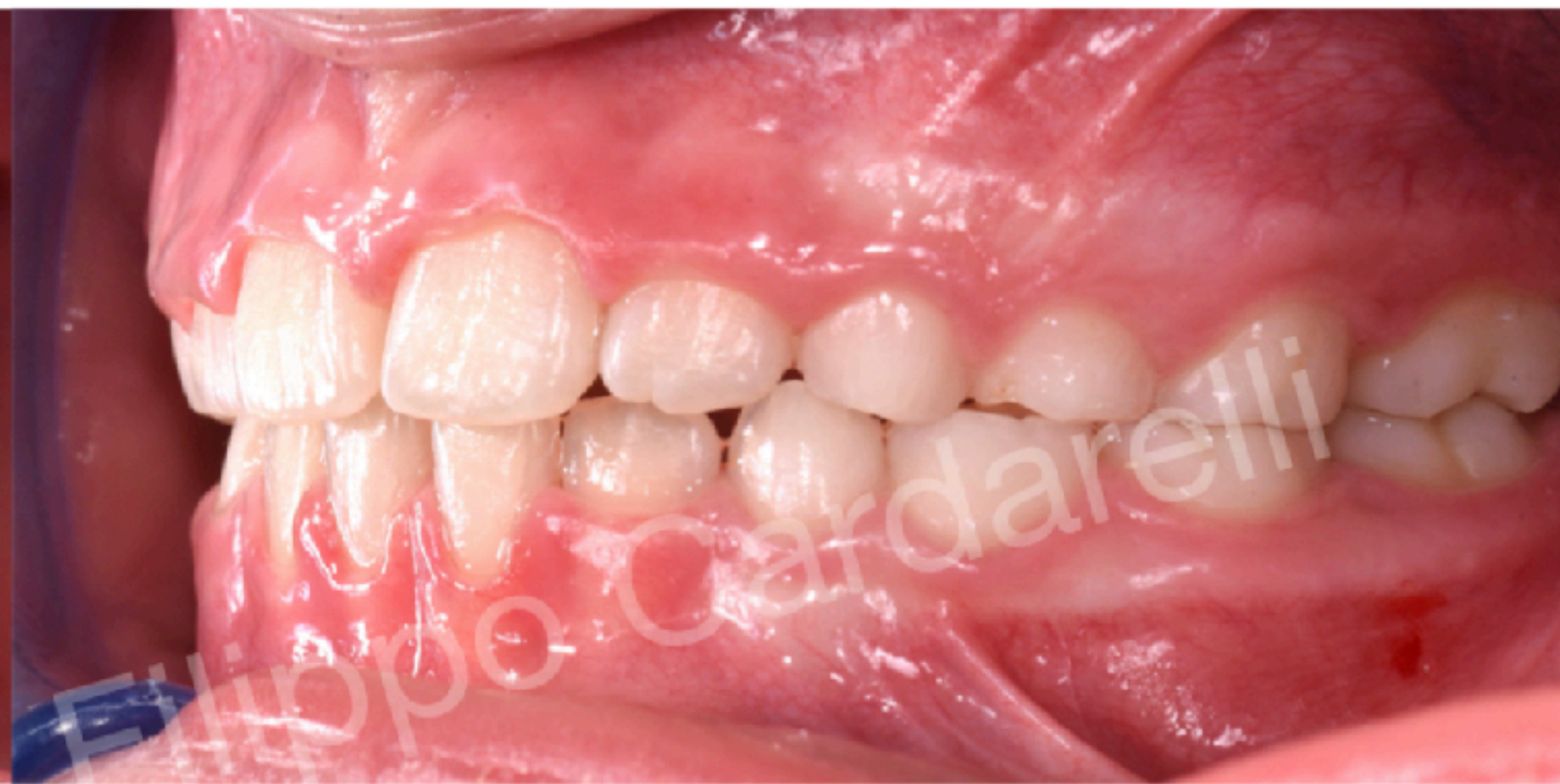
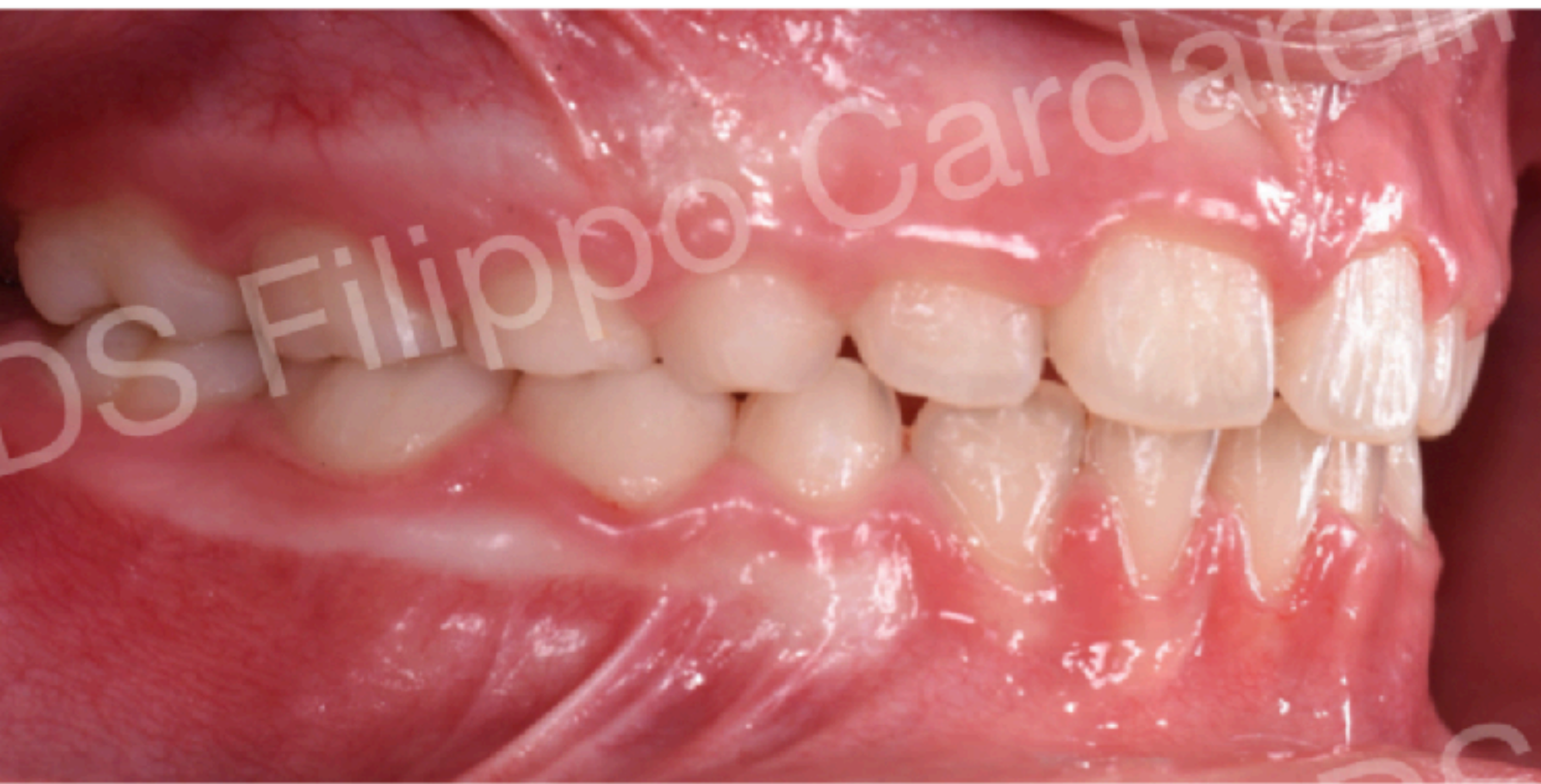
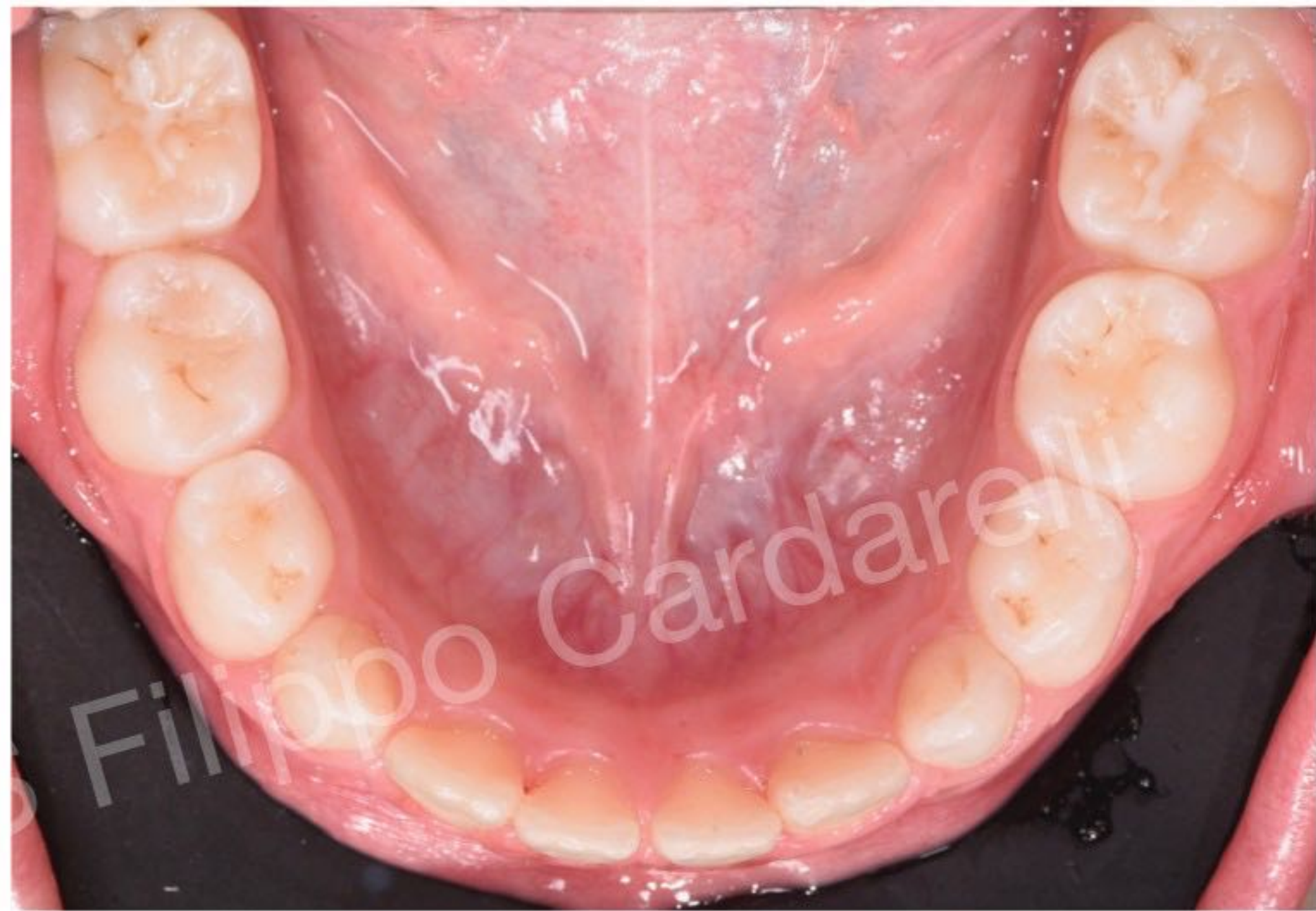
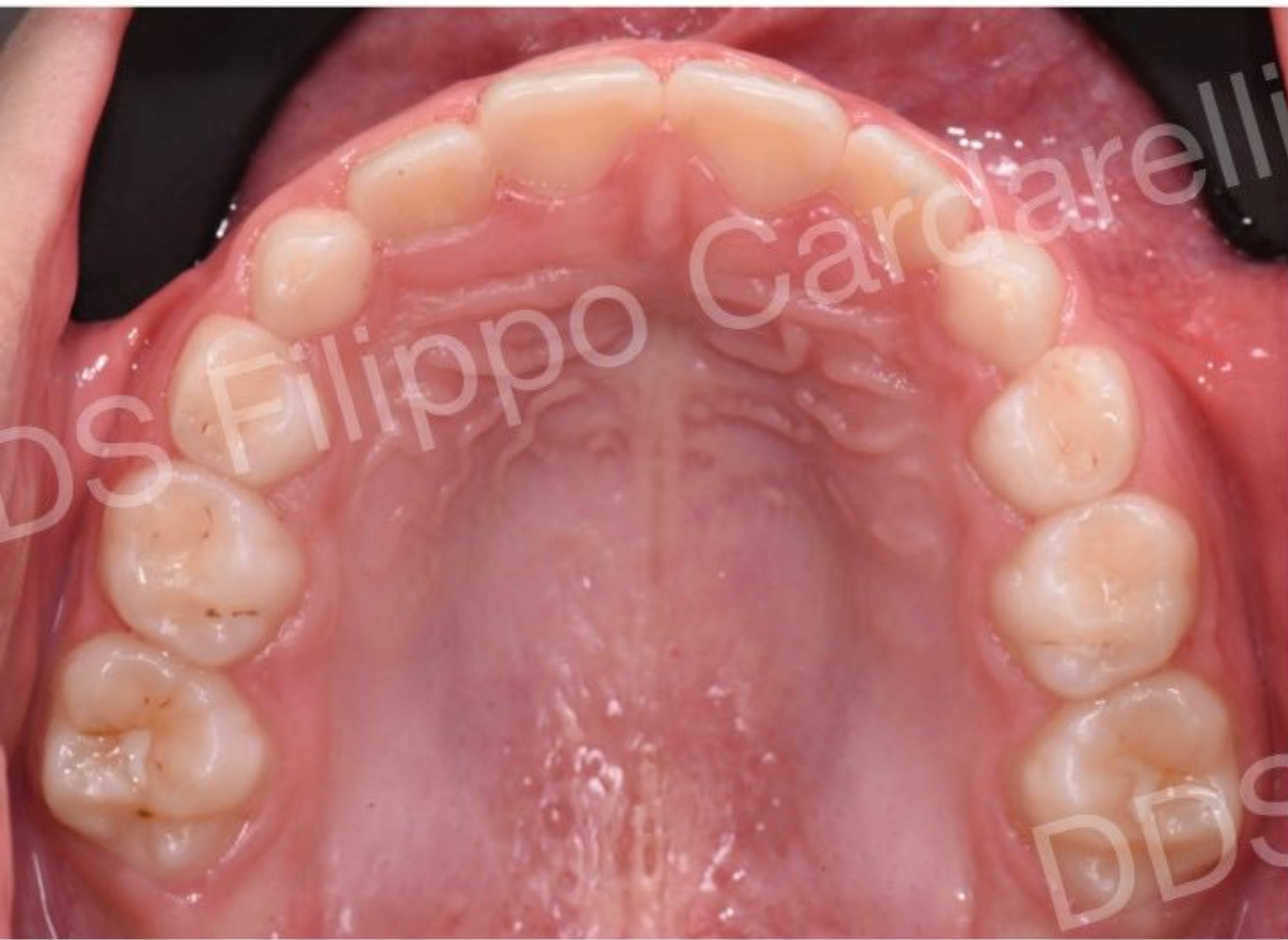DDS Filippo Cardarelli

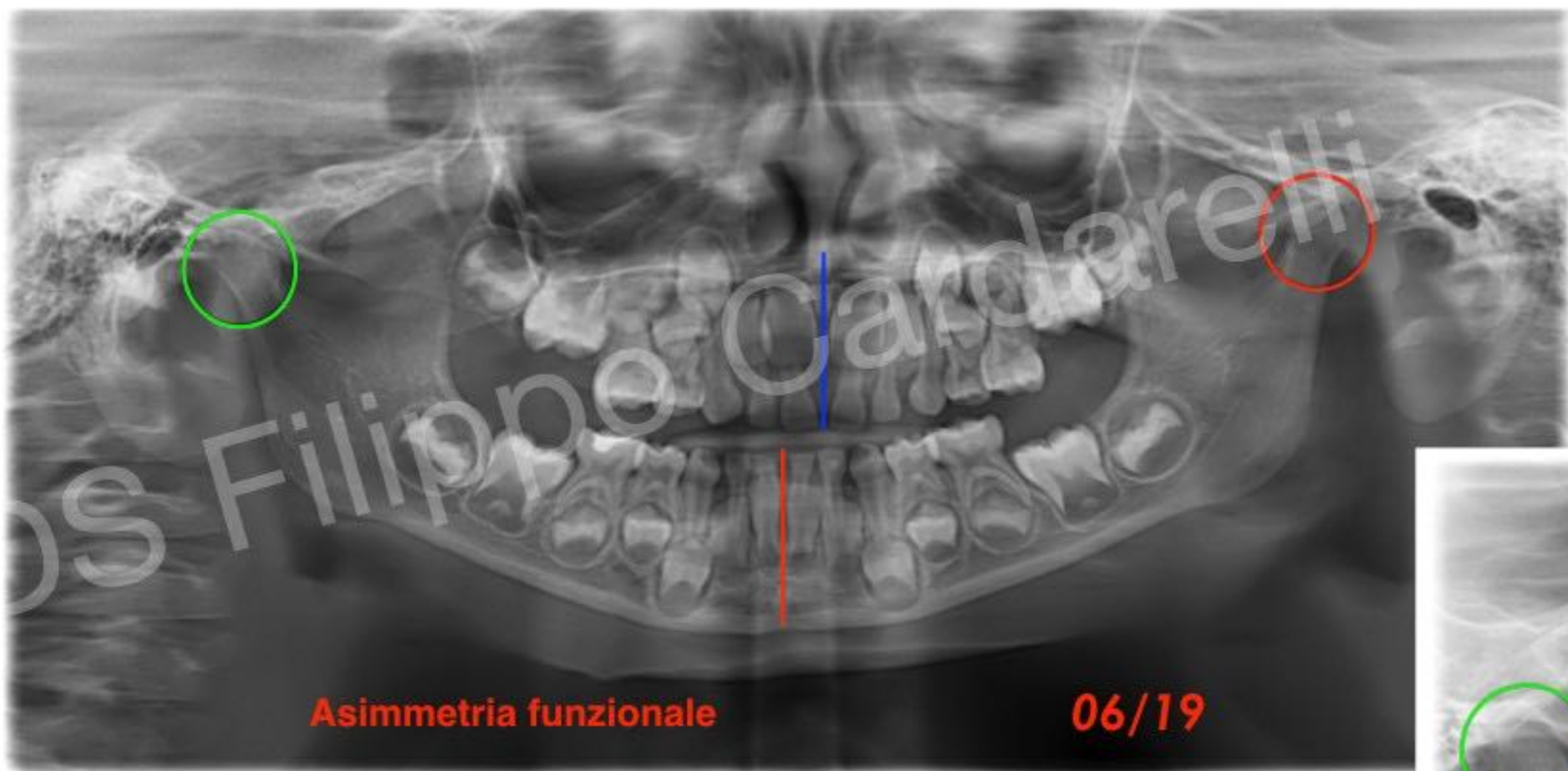
DDS Filippo Cardarelli







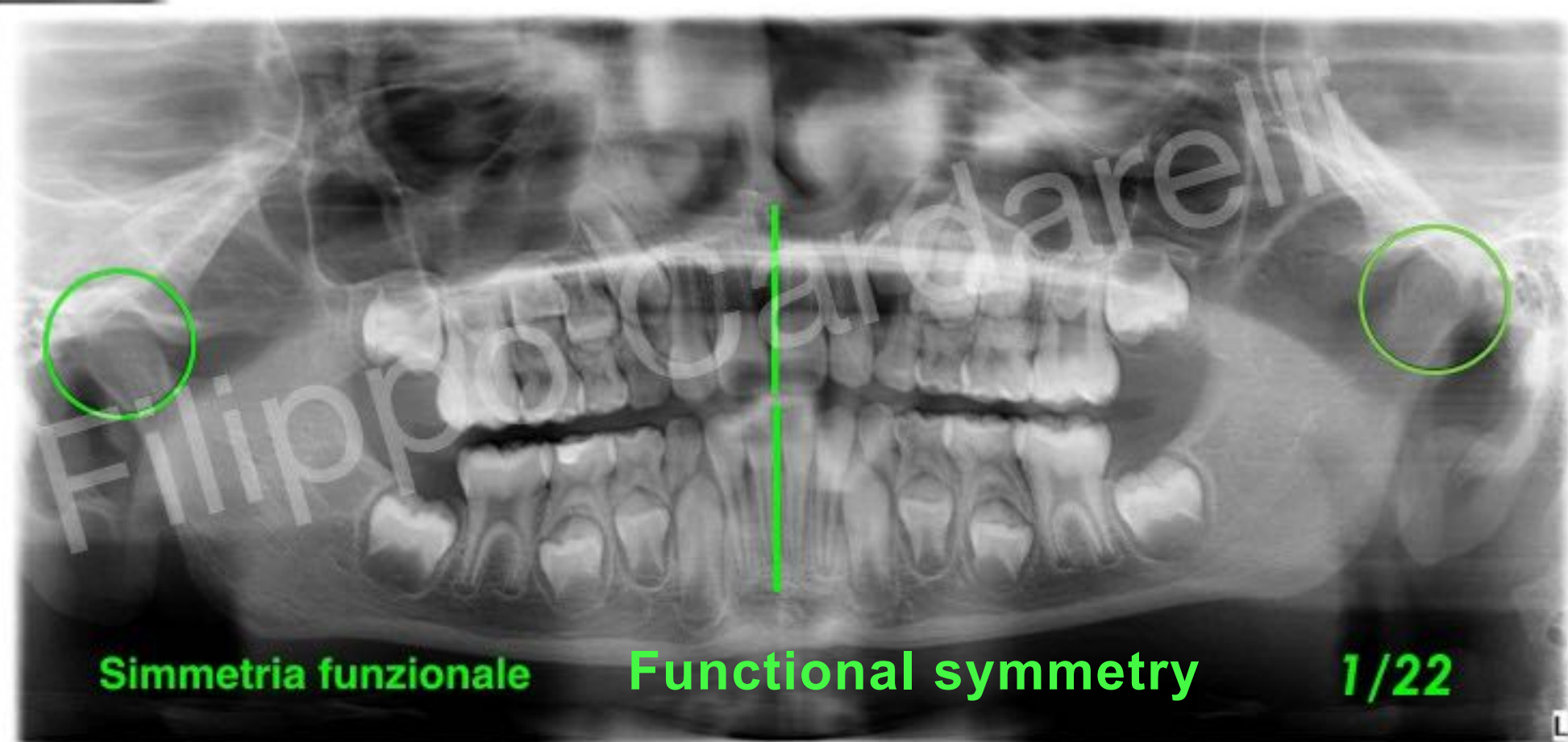




Asimmetria funzionale

06/19

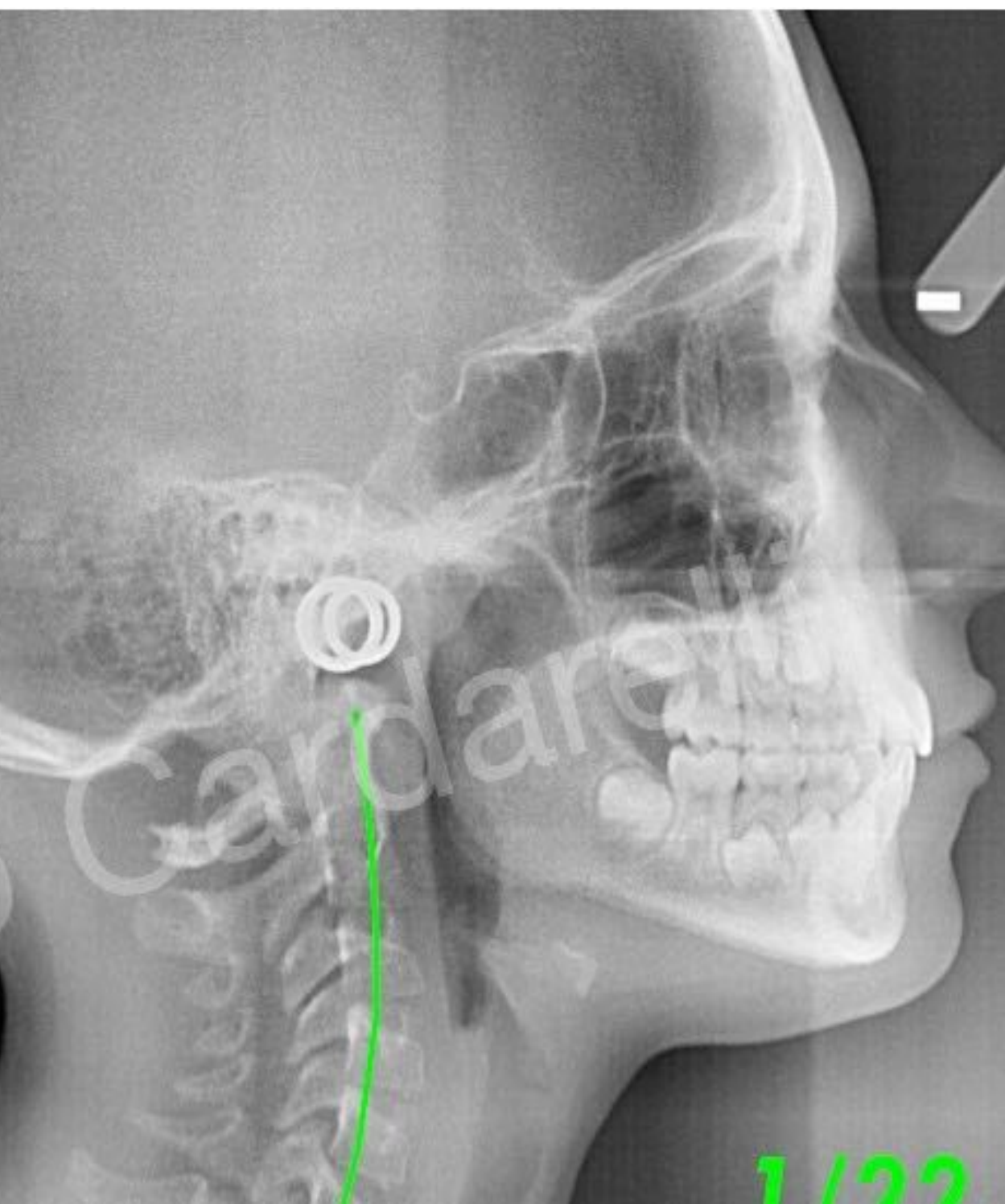
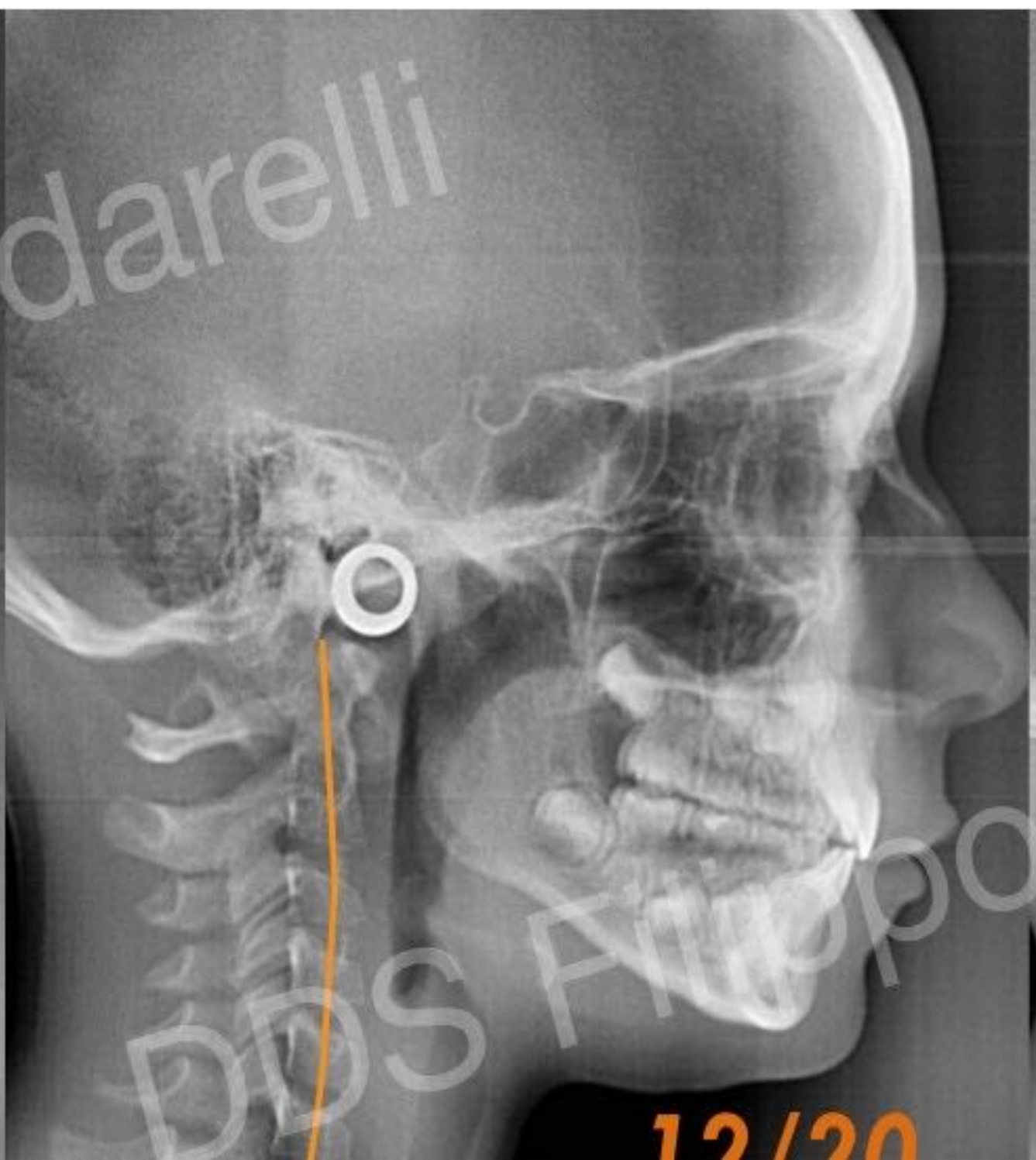
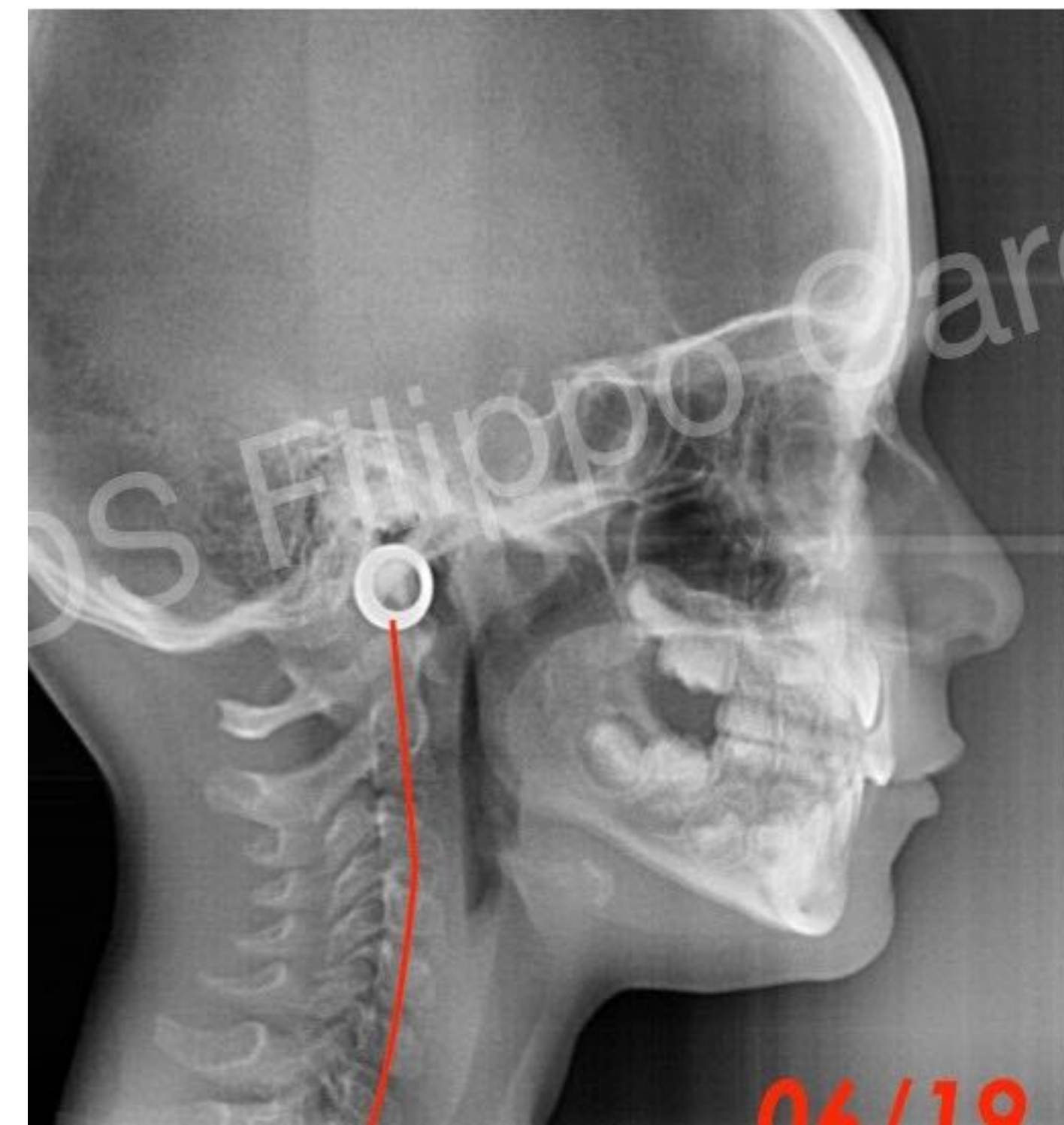
Functional asymmetry

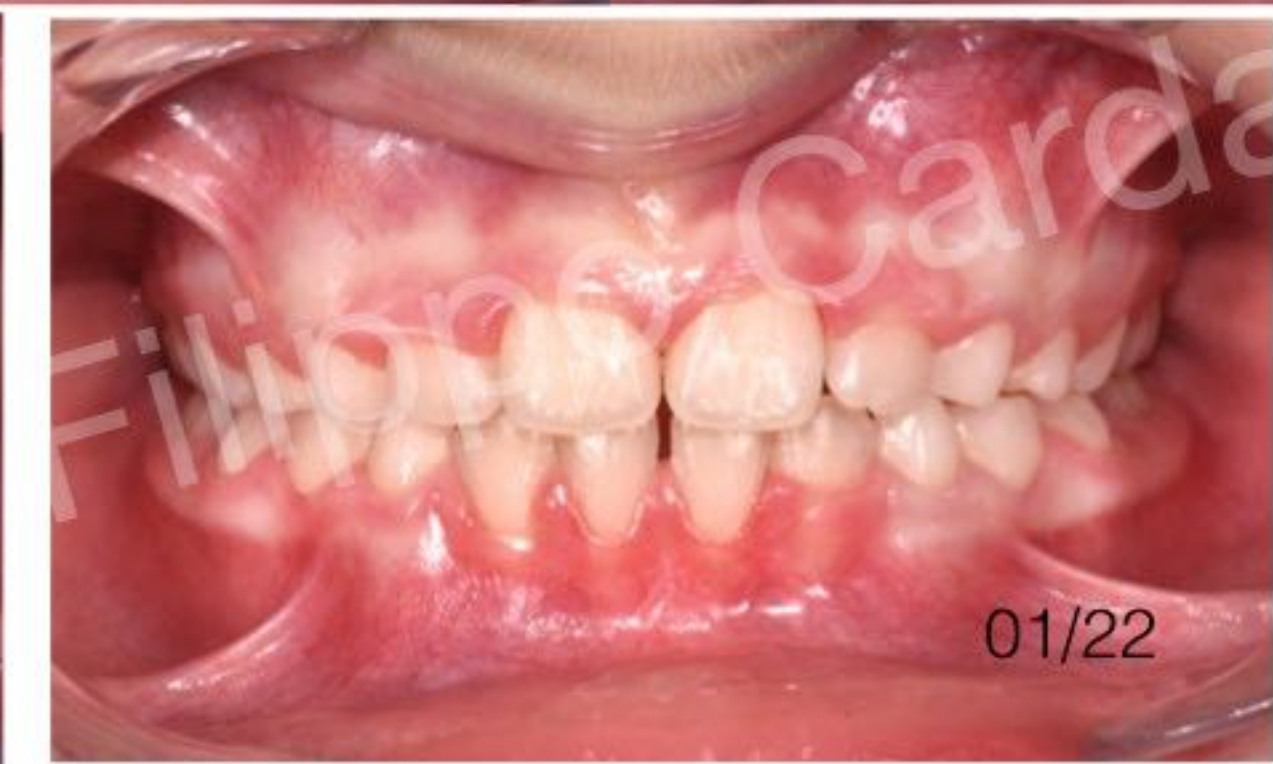
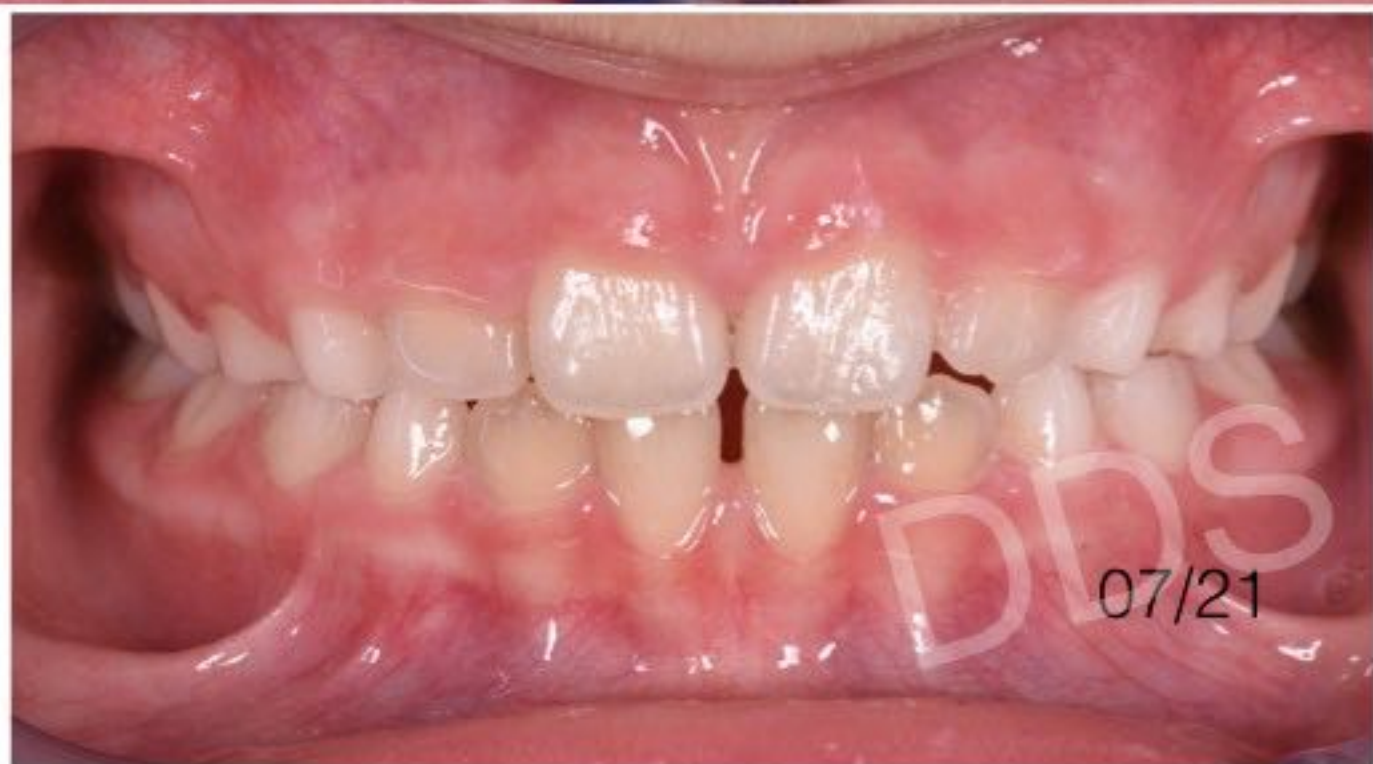
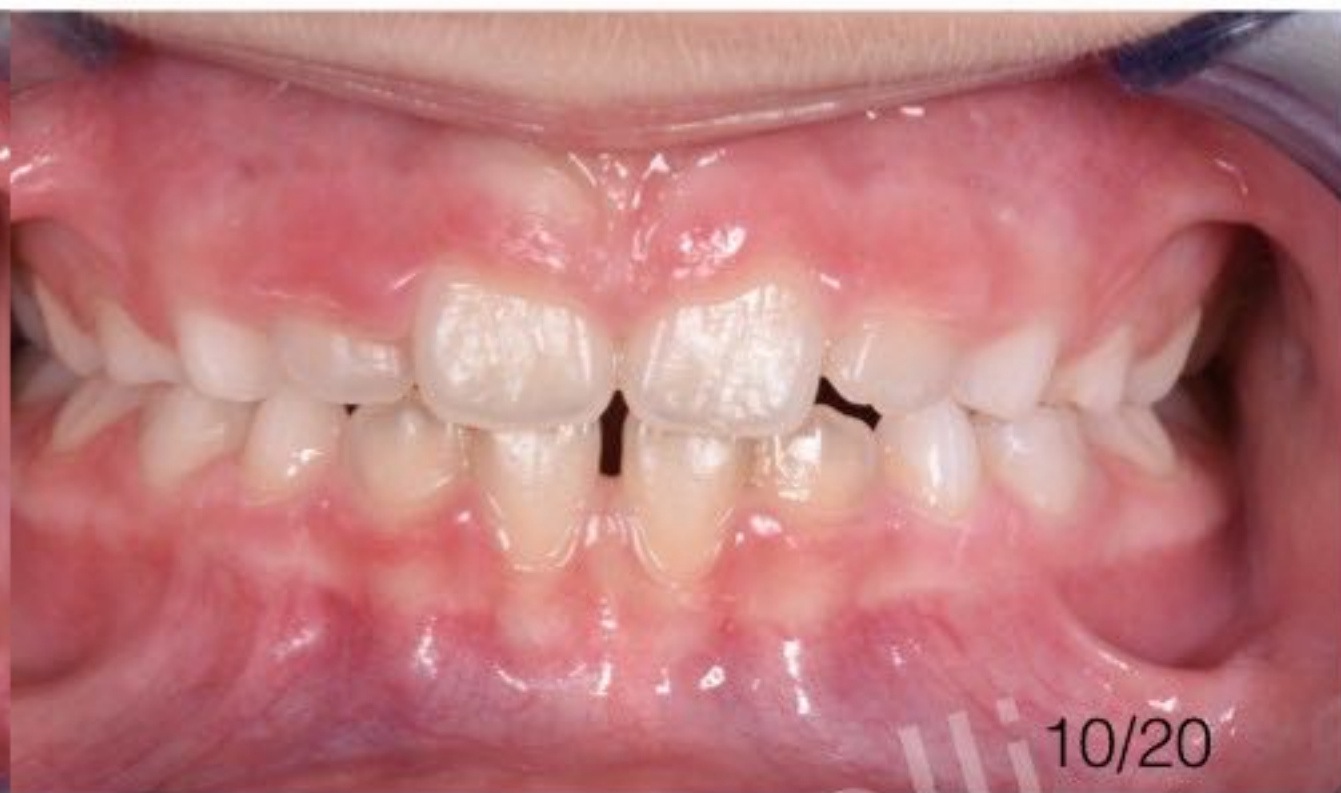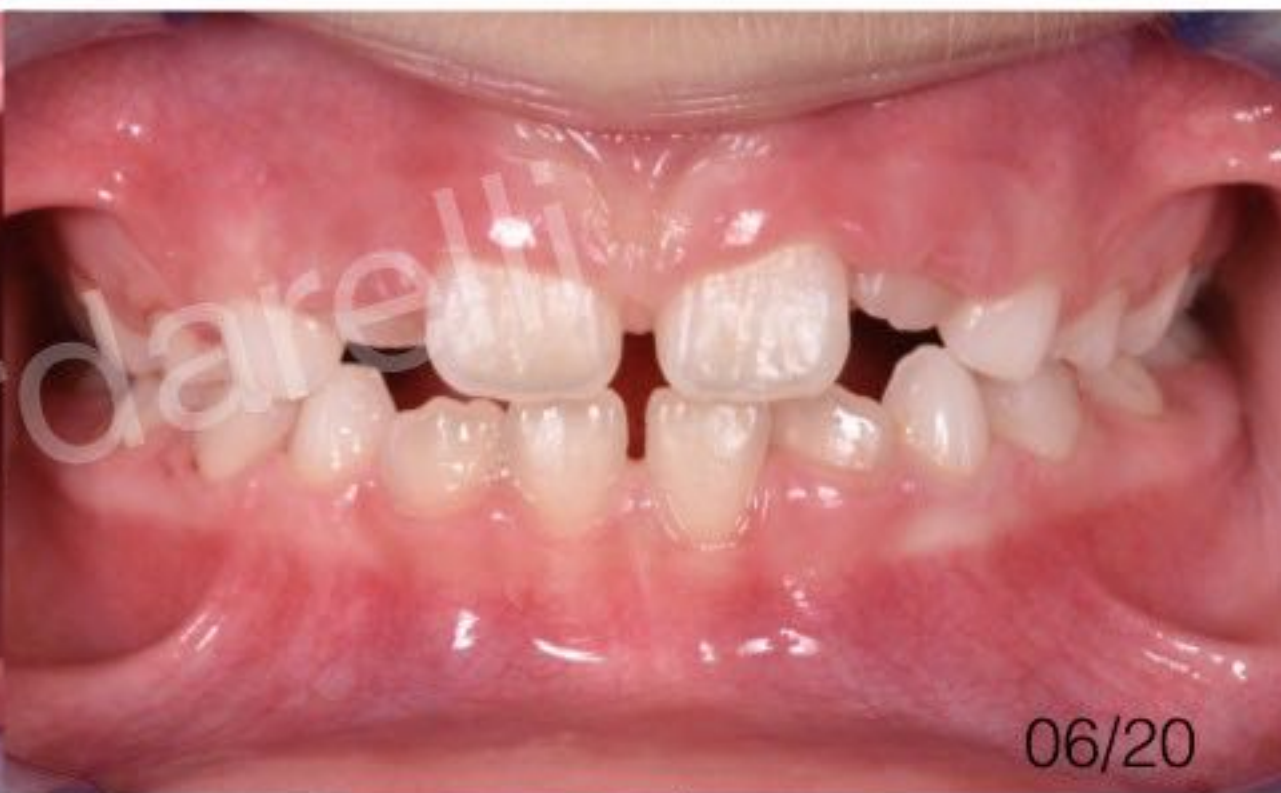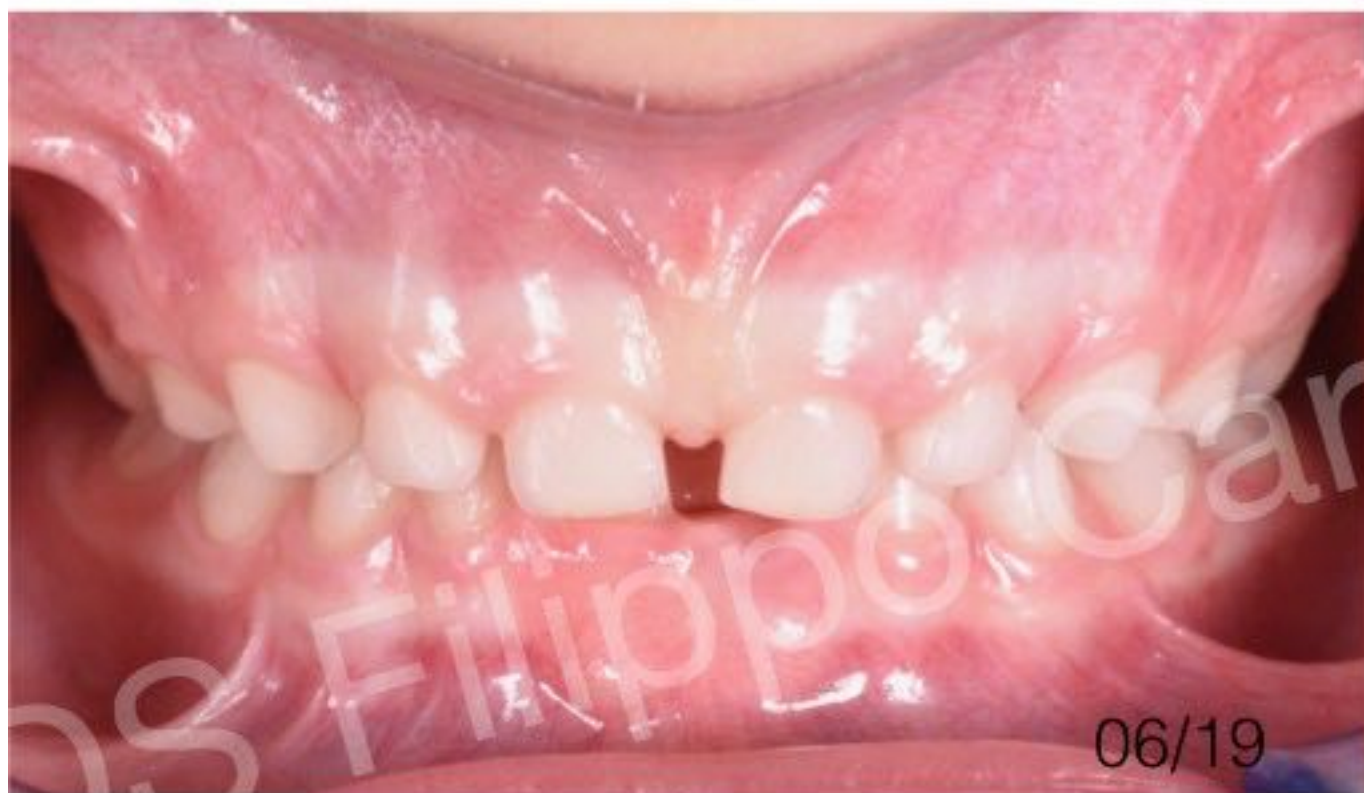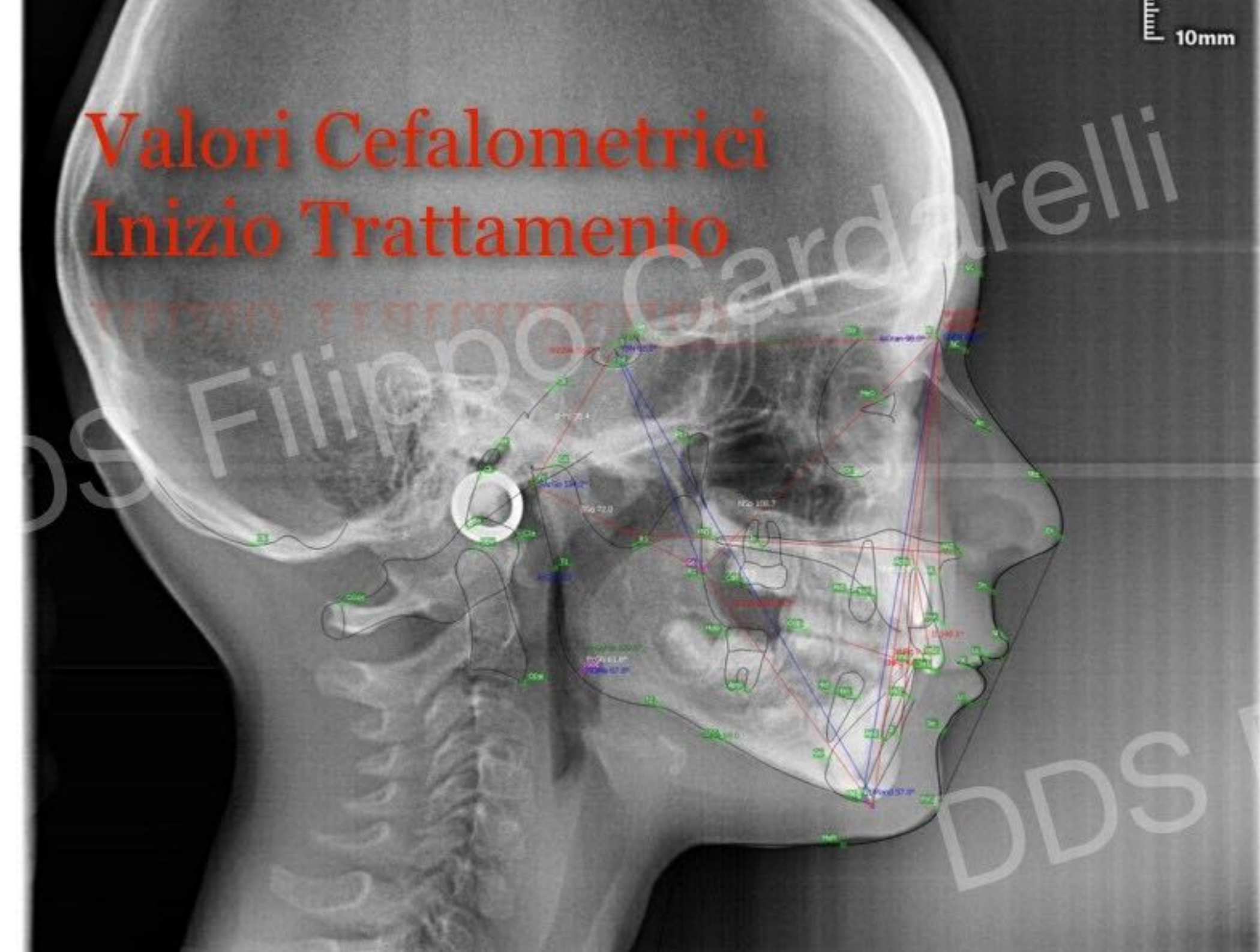
Simmetria funzionale

Functional symmetry

1/22

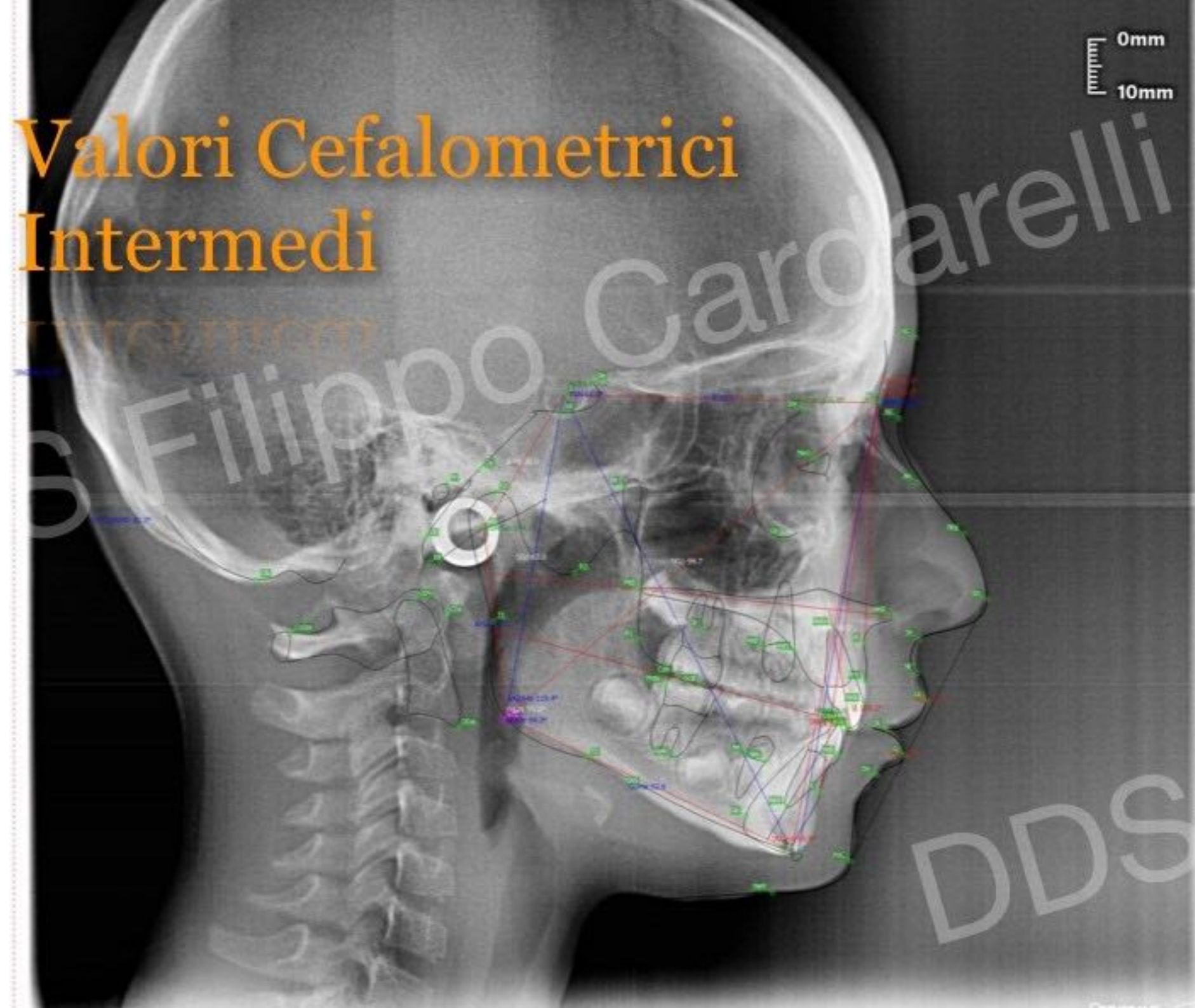






Cephalometric values Start of Treatment

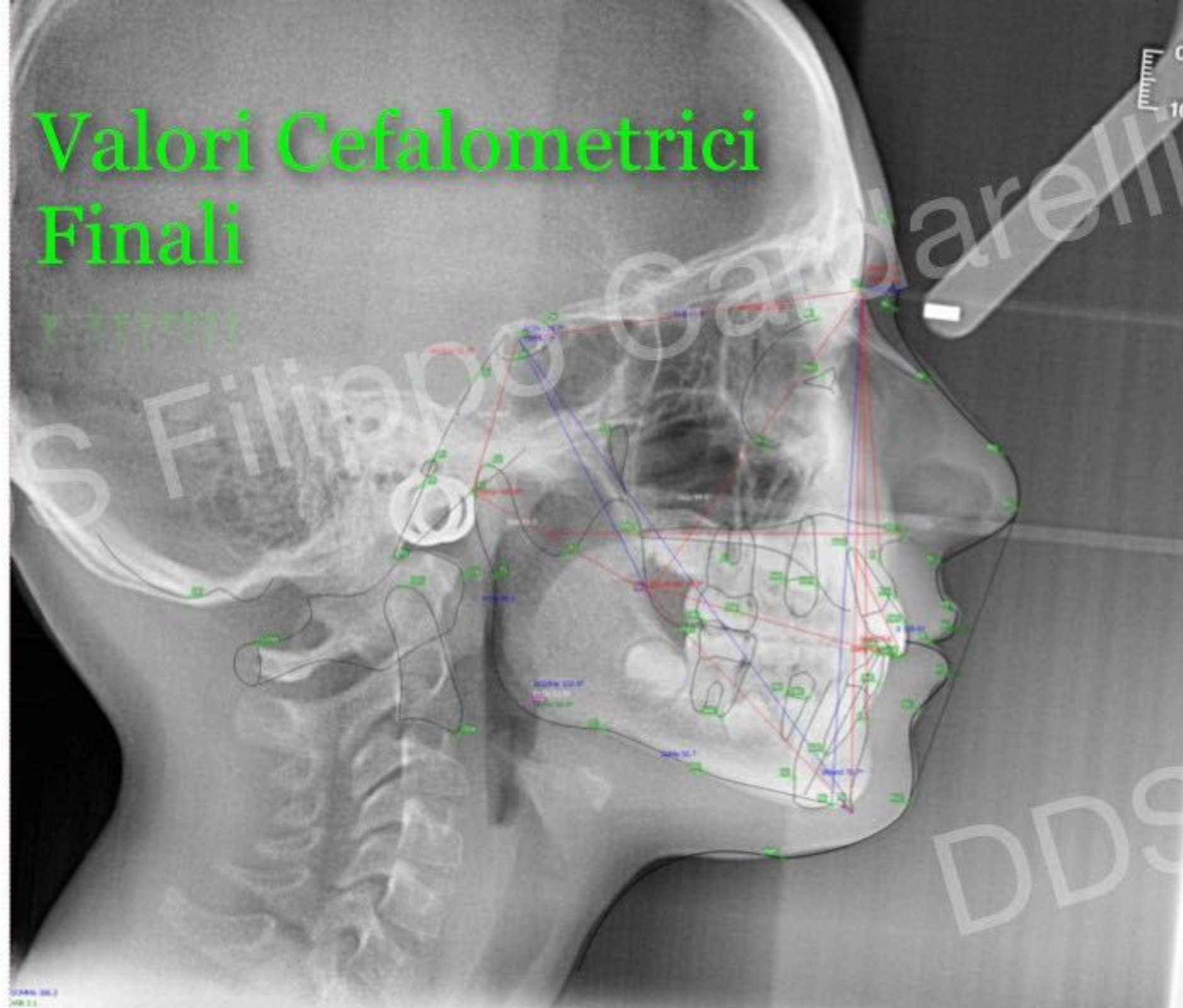
ANB	7,0
SNA	86,00
SNB	79,50
SArGo	144,0
ArGoMe	119,00
IiMand	96,00
IsCran	101,00
II	138,00



Intermediate cephalometric values

ANB	5,00
SNA	87,00
SNB	82,40
SArGo	134,0
ArGoMe	129,00
IiMand	62,00
IsCran	98,00
II	140,00

Valori Cefalometrici Finali



Final cephalometric values

ANB	3,0
SNA	82,00
SNB	79,00
SArGo	146,0
ArGoMe	122,00
IiMand	70,00
IsCran	104,00
II	126,00

Conclusions

Therapy of second skeletal and dental classes requires early intervention in order to promote proper vertical growth and mandibular positioning. In these cases, the high anterior chewing plane (Basic) can be used to increase vertical dimension, followed by the flat chewing plane (Integral). In the presence of parafunctions such as bruxism and in the presence of normal skeletal vertical dimension, it is preferable to use a flat mastication plane (Integral) in order to promote proper mandibular movement and increase in vertical dimension, which at this point will occur more slowly but in association with mandibular growth.